

Accreditation Statement

The University of Pittsburgh School of Medicine is accredited by the Accreditation Council for Continuing Medical Education (ACCME) to provide continuing medical education for physicians.

The University of Pittsburgh School of Medicine designates this enduring material for a maximum of 0.5 AMA PRA Category 1 Credits™. Each physician should only claim credit commensurate with the extent of their participation in the activity. Other health care professionals are awarded 0.05 continuing education units (CEU) which are equivalent to 0.5 contact hours.

Disclosures

Andrew M. Frederickson and Drs. Andrew F. Ducruet, Peter C. Gerszten, Brian T. Jankowitz, and Raymond F. Sekula Jr. have reported no relationships with proprietary entities producing health care goods or services. Dr. R. Mark Richardson reports grant and research support from Medtronic, Inc., and Erin E. Paschel is a consultant for Medtronic and Centinel Spine.

Instructions

To take the CME evaluation and receive credit, please visit UPMCPHYSICIANRESOURCES.COM/Neurosurgery and click on the course *Neurosurgery News Winter 2014*.

Flow Diversion Pipeline®

by Andrew F. Ducruet, MD, and Brian T. Jankowitz, MD

In the years since the introduction of Guglielmi Detachable Coils (GDC), the practice of aneurysm treatment has evolved dramatically. In 2002, the International Subarachnoid Hemorrhage Trial (ISAT) results demonstrated significantly improved outcomes in patients with ruptured aneurysms treated with coil embolization relative to surgical clipping. Although these results only applied to the subset of ruptured aneurysms that were thought to be equally well-suited for treatment by either coiling or clipping, the use of coil embolization to treat both ruptured and unruptured cerebral aneurysms has increased dramatically across the world. In response to what was viewed as the limited applicability of the ISAT results, neurosurgeons at the Barrow Neurological Institute undertook their own trial, which aimed to randomize all patients with subarachnoid hemorrhage to either coil embolization or microsurgical clipping, but allowing for crossover to the alternative treatment if deemed appropriate by the practitioner. The one-year follow-up results of this trial revealed a similar reduction in poor outcomes for those patients treated with endovascular coiling. This study reaffirmed the benefit of a coil-first policy for those patients with ruptured aneurysms thought to be anatomically suited for coil embolization.

In both of these trials and in daily practice, however, a significant proportion of aneurysms remains anatomically unfavorable for coil embolization. Over the last several years, the adjunctive use of balloon remodeling and stent-supported coil embolization, as well as newer coils with complex three-dimensional and variable shapes, have




Figure 1. Pipeline® embolization device demonstrating the braided nitinol strands. Used with permission from Covidien, Inc.

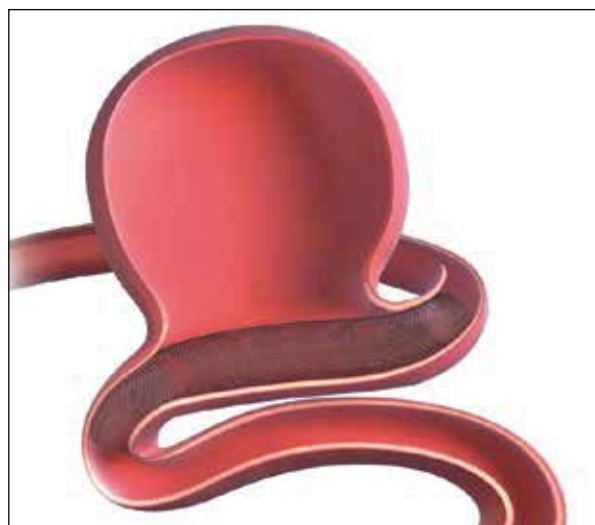

Figure 2. Schematic of the Pipeline positioned across the base of a broad-necked aneurysm. Used with permission from Covidien, Inc.

facilitated endovascular treatment of an increasingly broad array of anatomic configurations. However, large aneurysms with wide necks continue to challenge our ability to achieve

(Continued on back page)

Free Online CME

To receive CME credit, view this issue online at UPMCPHYSICIANRESOURCES.COM/Neurosurgery.

Editor's Message

Neurosurgery News Takes On a New Look



Welcome to the new and improved University of Pittsburgh Department of Neurological Surgery *Neurosurgery News*. After 14 years of serving as an important and effective means of communicating the many activities of the department, we have decided to update our look and make our newsletter even more

beneficial to our readership. We will continue to provide topical discussions of the latest techniques and outcomes in neurological surgery, but with some exciting changes in appearance, content, and features.

Most importantly, as a new feature of *Neurosurgery News* — and to further benefit physicians who read our newsletter — we offer a free CME course for this issue online. To take the evaluation and receive credit, visit UPMCPhysicianResources.com/Neurosurgery and click on the course *Neurosurgery News Winter 2014*.

As you can see from our large number of academic and clinical faculty, the University of Pittsburgh Department of Neurological Surgery continues to expand and flourish. We provide the latest in neurosurgical care to patients from the western Pennsylvania area, from across the country, and from around the globe. We have many groundbreaking clinical, translational, and basic science research activities under development or now performed by our faculty and staff.

Andrew F. Ducruet, MD, who joined our department this past year, and Brian Jankowitz, MD, from our endovascular service, describe

how our endovascular experts use the very latest flow-diverting devices to treat intracranial aneurysms previously not amenable to endovascular techniques. Raymond F. Sekula Jr., MD, head of our Center for Cranial Nerve and Brainstem Disorders, describes his work to demonstrate the safety and efficacy of treating very elderly patients with microsurgical techniques for disabling facial pain and hemifacial spasm. R. Mark Richardson, MD, PhD, director of our Epilepsy and Movement Disorders Program, describes the latest minimally invasive techniques used to precisely locate the focus of seizure activity within the brain and thus allow for surgical removal. Finally, our spine surgeons are carefully evaluating the latest techniques of zero-profile instrumentation for anterior cervical discectomy and fusion surgery instead of the more standard use of plates for stabilization.

Within these pages, we have attempted to demonstrate the breadth of our cutting-edge work in the field of neurological surgery. Such techniques being invented, developed, or carefully evaluated by members of our faculty will eventually be presented at national and international meetings and ultimately published in the peer-reviewed literature. How we practice neurosurgery today will be reflected in how neurosurgery will be performed in the region, around the country, and internationally for years to come.

For further information regarding the myriad of activities within our department, we encourage readers to visit our website at neurosurgery.pitt.edu.

Peter C. Gerszten, MD, MPH

Peter E. Sheptak Professor of Neurological Surgery

Faculty

Chairman

Robert M. Friedlander, MD, MA

Professors

C. Edward Dixon, PhD
(Vice Chairman, Research)
Peter C. Gerszten, MD, MPH
Larry W. Jenkins, PhD
L. Dade Lunsford, MD
John J. Moossy, MD
Hideho Okada, MD, PhD
Ian F. Pollack, MD
(Vice Chairman,
Academic Affairs)
Mingui Sun, PhD

Associate Professors

Jeffrey Balzer, PhD
Paul A. Gardner, MD
Ajay Niranjan, MD, MBA
David O. Okonkwo, MD, PhD

Assistant Professors

Nduka Amankulor, MD
David J. Bissonette, PA-C, MBA
(Executive Administrator)
Diane L. Carlisle, PhD
Donald J. Crammond, PhD
Andrew F. Ducruet, MD

Johnathan Engh, MD
Juan C. Fernandez-Miranda, MD
Avniel Ghuman, PhD
Paola Grandi, PhD
Stephanie Greene, MD
Miguel Habeych, MD, MPH
Brian Jankowitz, MD
Adam S. Kanter, MD
Edward A. Monaco III, MD, PhD
Jamie Pardini, PhD
Ava Puccio, PhD, RN
Shengjun Ren, PhD
R. Mark Richardson, MD, PhD
Raymond F. Sekula Jr., MD, MBA
Mandeep Tamber, MD, PhD
Elizabeth C. Tyler-Kabara,
MD, PhD
Yu Zhang, PhD

Clinical Professors

Adnan A. Abba, MD
Matt El-Kadi, MD, PhD
(Vice Chairman)
Joseph C. Maroon, MD
Daniel A. Wecht, MD, MSc

Clinical Associate Professor

Michael J. Rutigliano, MD, MBA

Clinical Assistant Professors

Eric M. Altschuler, MD
J. Brad Bellotte, MD
J. William Bookwalter III, MD
Daniel M. Bursick, MD
David J. Engle, MD
David L. Kaufmann, MD
Parthasarathy D. Thirumala, MD
Matthew M. Wetzel, MD

Research Assistant Professors

Yue-Fang Chang, PhD
Wendy Fellows-Mayle, PhD
Esther Jane, PhD
Wenyan Jia, PhD
Hideyuki Kano, MD, PhD
Rekha Pal, MD
Daniel Premkumar, PhD
Hong Qu Yan, MD, PhD

Clinical Instructor

Jeff Bost, PA-C

Chief Residents

Christopher Bonfield, MD
Ramesh Grandhi, MD

Contact Us

Brain Function & Behavior
412-647-7744
Brain Tumor
412-647-2827
Carotid Disease
412-647-2827
Cerebrovascular
412-647-2827
Clinical Neurophysiology
412-647-3450
Cranial Nerve Disorders
412-647-3920
Donations
412-647-7781
Endonasal Surgery
412-647-6778
Endovascular
412-647-7768
Gamma Knife®
412-647-7744
MEG Brain Mapping Center
412-648-6425
Movement Disorders
412-647-7744

Neurosurgical Oncology
412-647-8312
Pediatric Neurosurgery
412-692-5090
Referrals
412-647-3685
Residency Program
412-647-6777
Spine
412-802-8199
Spine Radiosurgery
412-647-9786
UPMC Mercy Neurosurgery
412-471-4772
Editor: Peter C. Gerszten,
MD, MPH
Production Editor: Paul Stanick

Department of Neurological Surgery

UPMC Presbyterian
Suite B-400
200 Lothrop St.
Pittsburgh, PA 15213

Website: neurosurgery.pitt.edu

Email: neuroinfo@upmc.edu

Zero-Profile Anterior Cervical Discectomy and Fusion Device Instead of Standard Plate Fixation

by Peter C. Gerszten, MD, MPH, and Erin E. Paschel, PA-C

A herniated disc in the cervical spine is most often the result of the normal aging process, called degenerative disc disease. It can also be due to a more acute event such as direct trauma to the cervical spine. The disc herniates posteriorly into the spinal canal, putting pressure on the spinal cord or the exiting nerve roots that supply sensation and motor control to the arms and hands. Symptoms of a cervical herniated disc can include pain in the neck, shoulders, arms, and hands; weakness of the arms or legs; numbness and tingling in the upper extremities; and difficulty walking or imbalance. Non-surgical treatments for cervical disc herniations include a short course of oral steroids, physical therapy, chiropractic care, steroid injections, and pain medication. When these modalities fail to improve symptoms over time, surgical intervention is considered.

Anterior cervical discectomy and fusion (ACDF) has been the standard surgical treatment for degenerative conditions of the cervical spine, including degenerative disc disease and cervical spondylotic myelopathy, for almost half a century. Considerable research has demonstrated the efficacy of the ACDF procedure with plate fusion for the treatment of cervical disc herniations with successful resolution of preoperative symptoms. ACDF is a well-accepted treatment for patients experiencing neck and arm symptoms due to degenerative disc disease of the cervical spine. This procedure has long been performed by making an incision in the front of the neck, removing the diseased disc, and inserting an interbody device in its place to maintain intervertebral disc height and encourage fusion across the vertebral bodies. The implant is frequently held in place with a titanium plate anchored by screws. Studies have shown that the addition of an anterior plate with screws to an interbody cage or spacer provides enhanced stability and increased fusion rates.

Although successful in achieving fusion, anterior plating is not without complications. Dysphagia is the most common postoperative complication, and it has been linked to the anterior prominence associated with plate and screw constructs and the adhesions that form in response to the plate. The risk of complications with the ACDF surgery increases substantially with a multi-level discectomy and plate fusion, as a larger incision is necessary to adequately dissect the cervical spine and place the plate across multiple vertebral bodies. This increases the potential for greater blood loss during the procedure, as well as postoperative wound infection. By eliminating the need for a cervical plate, a smaller incision can be used, allowing for less manipulation of the airway, vocal cords, esophagus, and vascular structures. This more minimally invasive approach allows for a decrease in the rate of complications and shortens the length of hospital stay.



STALIF C® provides stable fixation of motion. An integrated screw design avoids the need for cervical plating while providing the necessary rigidity for cervical spinal fusion.

Used with permission from Centinel Spine

In an effort to reduce the potential complications associated with these plate constructs, surgeons in the Department of Neurological Surgery have adopted a novel technique using a zero-profile interbody fixation device that eliminates the need for an anterior plate after a discectomy procedure. The STALIF C® (Centinel Spine, West Chester, Pa.) is a radiolucent cervical integrated interbody fusion device constructed of polyether-ether-ketone (PEEK) with three integrated cancellous screws designed to provide lag compression between the adjacent vertebral bodies and confer anterior column fixation. The design avoids the need for any additional internal fixation devices while providing the segmental rigidity necessary for cervical spinal fusion.

This zero-profile device is contained entirely within the disc space and does not protrude past the anterior wall of the vertebral body, as an anterior cervical plate does. This minimizes soft tissue irritation and contact with the esophagus and vocal cords. The risk of future complications in adjacent levels of the cervical spine is also theoretically minimized, as it has been shown that cervical plates placed near an adjacent level may lead to bone formation and degeneration of that adjacent disc. This device is biomechanically similar to a cage and plate fusion, providing the patient with immediate mechanical stability while reducing the morbidity associated with plate fusion.

(Continued on page 5)

Cranial Nerve Disorders in the Elderly

by Raymond F. Sekula Jr., MD, MBA, and Andrew M. Frederickson, MS

The golden years ought to be an enjoyable time, but for patients suffering from trigeminal neuralgia (TN) and hemifacial spasm (HFS) life can become unbearable. Both of these disorders, which disproportionately affect older patients, are of particular interest at the Center for Cranial Nerve and Brainstem Disorders. TN and HFS are debilitating conditions that can severely reduce the quality of life of patients. Each affecting only one side of the face, TN and HFS result in searing jolts of pain and severe spasms, respectively. Since both disorders are typically caused by a blood vessel compressing the corresponding cranial nerve, surgeons performing an operation called microvascular decompression (MVD) can cure each disorder by interposing a synthetic barrier between the blood vessel and nerve.

A recent focus for the Center has been on improving the standard of care for elderly patients (over the age of 65) with trigeminal neuralgia or hemifacial spasm. Although microvascular decompression offers the best chance of a long-term cure with minimal morbidity, many patients over the age of 65 have been advised to avoid MVD because of a higher perceived risk in this subpopulation. As a result of this belief, elderly patients with TN are often offered a percutaneous procedure such as radiofrequency rhizotomy, glycerol rhizotomy, or balloon compression when medications fail. While such procedures are less invasive than MVD, they are also damaging to the trigeminal nerve and trade pain relief for sensory side effects. Because pain often recurs within several years of one of these procedures, they usually must be repeated many times. After all, many 65-year-old patients will live for another two decades. With each repeated procedure, the chance of devastating sensory dysfunction increases.

Additionally, elderly patients with hemifacial spasm often receive botulinum toxin therapy only. While many patients are satisfied with this treatment, many become frustrated because it does not provide a long-term cure and it weakens the facial muscles. Finally, some elderly patients with cranial neuropathies are offered no treatment at all.

Our team has recently published two prospective studies—one for trigeminal neuralgia and one for hemifacial spasm—showing that not only can elderly patients markedly benefit from MVD, but also that these benefits do not appear to come with any greater risk than in younger patients (Tables 1 and 2). In our practice, even patients in their eighties routinely undergo MVD with low morbidity. Although scrupulous patient selection is important in any surgical endeavor, the criteria for elderly patients need not be any more stringent than in younger patients. Additionally, thanks to recent advances in anesthesia techniques and the availability of an experienced team to care for post-MVD patients, patients in both the young and the elderly groups had a median hospital stay of only two days without the use of intensive care.

As a result of this focus, the Center has accrued substantial experience with microvascular decompression and other procedures in elderly patients. Recent and ongoing operative innovations include the use of endoscopy to improve visualization and surgery without rigid head fixation or retractors.

For further information regarding comprehensive surgical treatment of cranial neuralgias, please contact Ann Wilkinson, RN, at 412-647-3920.

Table 1: Complications of MVD for TN in the Elderly Cohort

Complication	No. of Patients (%) N=36
Numbness	5 (13.9%)
New or worsened dysesthesias	2 (5.7%)
Death	0
Cerebellar hematoma	0
Stroke	0
Hyponatremia	2 (5.7%)

Table 2: Complications of MVD for HFS in the Elderly and Non-elderly Cohorts

Complication	Elderly No. of patients (%) N=27	Non-elderly No. of patients (%) N=104
Death	0	0
Stroke	0	1 (1.0%)
Cerebellar hematoma	0	1 (1.0%)
Immediate facial weakness (transient/permanent)	1 (3.7%)/1 (3.7%)	5 (4.8%)/1 (1.0%)
Delayed facial weakness (transient/permanent)	1 (3.7%)/0	11 (10.6%)/1 (1.0%)
Vestibular nerve dysfunction (transient/permanent)	1 (3.7%)/0	1 (1.6%)/2 (1.9%)
Unilateral hearing loss (partial/complete)	2 (7.4%)/0	2 (1.9%)/3 (2.9%)
Dysphagia or hoarseness (transient/permanent)	4 (14.8%)/0	3 (2.9%)/2 (1.9%)

Table 1:

Adapted from Sekula RF Jr, Frederickson AM, Jannetta PJ, Quigley MR, Aziz KM, Arnone GD. Microvascular decompression for elderly patients with trigeminal neuralgia: a prospective study and systematic review with meta-analysis. *J Neurosurg.* 2011 Jan;114(1):172-9.

Table 2:

Adapted from Sekula RF Jr, Frederickson AM, Arnone GD, Quigley MR, Hallett M. Microvascular decompression for hemifacial spasm in patients >65 years of age: an analysis of outcomes and complications. *Muscle Nerve.* 2013 Nov;48(5):770-6.

2013 Congress of Neurological Surgeons: Annual Meeting Presentations

The University of Pittsburgh Department of Neurological Surgery was well-represented at the 2013 Congress of Neurological Surgeons annual meeting recently in San Francisco, Calif. Following is a list of faculty and resident presentations.

Practical Courses

Building a Neurosciences Program. Adelson PD, Ecklund JM, Friedlander RM, Pracyk J, Steinberg GK.

Science Programs and Seminars

Section on Cerebrovascular Surgery. *The Evolution of Neurosurgery.* Friedlander RM, Lunsford LD, Marayama Y, Steinberg GK, Turner RD IV.

Synthes Skull Base Award. *Chondrosarcoma Radiosurgery: Report of the North American Gamma Knife Consortium.* Kano H, Sheehan JP, Sneed P, McBride H, Young AB, Duma CM, Mathieu D, McDermott MW, Iyer AK, Lunsford LD.

Long Term Outcomes of Dorsal Root Rhizotomy for Refractory Occipital Neuralgia.

Gande A, Moosy JJ, Horowitz MB, Rothfus WE, Gardner PA.

Reversal of Pre-Morbid Oral Anti-Platelet Therapy Is Not Associated with a Decrease in Radiographic Progression of Intracranial Injury. Bauer JS, Panczykowski DM, Zusman B, Grandhi R, Chang Y, Puccio A, Okonkwo DO.

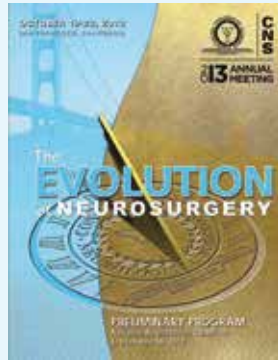
Association Between Posterior Cranial Fossa Volumetry and CSF Flow Dynamics in Chiari Malformations Type I. Alperin N, Lee SH, Bagci A, Sekula RF, Green BA.

Spinal Oncology: From Radiotherapy, Surgery, to Radiosurgery. Gerszten PC.

Skull Base Endoscopy: Utility and Limitations. Moderators: Gardner PA, Teo C. Faculty: Fernandez-Miranda JC, Gentili F, Peiper DR.

Operative Neurosurgery II: Intraoperative Complication Avoidance and Management. Moderators: Cohen-Gadol A, Gardner PA. Faculty: Barrow DL, Bulsara KR, Fessler RG, Lawton MT, Morcos JJ, Sekhar LN.

Section on Pain. *The Evolution of Pain Neurosurgery.* Moderator: Machado A, Piltis JG. Faculty: Mogilner AY, Patil PG, Slavin KV, Sekula RF.



Section on Neurotrauma and Critical Care. *Evolution of Neurosurgery: Translational Research to Clinical Trial.* Moderator: Harris O, Okonkwo DO. Faculty: Chesnut RM, Tsai E.

Presentations

Vertebral Body Fractures After Radiosurgery: A Large Multi-Institutional Experience. Faheem DK, Gerszten PC, Chen S, Flickinger JC, Saghal A, Grills IS, Sheehan JP, Kirsh CR.

Clinical and Radiographic Outcomes Following Reduction and Instrumented Fusion for High-Grade Spondylolisthesis – A Multicenter Experience. Kasliwal MK, Gandhoke GS, Nieto J, Park P, Shaffrey CI, Kanter AS.

The Role of Changes in Neurophysiologic Monitoring as a Predictor of Neurologic Deficit or Procedural Complication During the Endovascular Treatment of Cerebral Aneurysms. Balzer J, Ares WJ, He A, Winek N, Grandhi R, Jankowitz BT, Jovin T, Horowitz MB, Habeych M, Crammond D, Thirumala PD.

Use of the NICO Myriad Device for the Treatment of Loculated Hydrocephalus in Children. Foster KA, Tyler-Kabara EC.

Safety and Efficacy Evaluation of Balloon Kyphoplasty for Compression Fractures in the Very Elderly. Gandhoke GS, Paschel E, Deibert C, Gerszten PC.

Examining the Utility of Extended Strip Cranioplasty for the Treatment of Sagittal Synostosis: Cranial Index, Nasofrontal Angle, and Reoperation Rate. Bonfield CM, Lee P, Adamo MA, Pollack IF.

Transfusion Reversal of Pre-Morbid Oral Antiplatelet Use Is Not Associated with a Decrease in Radiographic Progression. Bauer J, Panczykowski DM, Zusman B, Grandhi R, Chang Y, Puccio A, Okonkwo DO.

Synthetic Enhancement of Temozolomide Sensitivity in MSH6-Deficient Glioblastoma Stem Cells by Poly (ADP-Ribose) Polymerase 1 Inhibition. Ricks C, Goodman L, Ezhilarasan R, Kaufman A, Cabral M, Narayanan R, Nutt C, Sulman EP, Cahill DP.

Radiographic and Clinical Outcomes Following Combined Lateral Lumbar Interbody Fusion and Posterior Segmental Stabilization in Patients with Adult Degenerative Scoliosis. Tempel Z, Bonfield CM, Gandhoke GS, Okonkwo DO, Kanter AS.

Safety and Efficacy of Percutaneous Femoral Artery Access Followed by Mynx Closure in Cerebral Neurovascular Procedures: A Single-Center Analysis. Miller RA, Grandhi R, Kanaan H, Shah AC, Harrison G, Jovin T, Jankowitz BT, Horowitz MB.

Zero-Profile (continued from page 3)

In order to carefully evaluate this new technique, a prospective investigation was performed on all patients who underwent implantation of the zero-profile STALIF C device instead of a cervical plate fixation for both single-level and multi-level cervical discectomy surgery starting in January 2011. The primary indication for surgery was symptoms of radiculopathy and/or myelopathy due to a herniated disc that had failed nonsurgical measures of treatment. The mean age of patients undergoing surgery was 54 years old, with ages ranging from 28 to 69 years. Cervical fusion was assessed at three months using anteroposterior and lateral plain radiographs. Self-reported outcomes were measured using patient questionnaires, including the SF-12, the Neck Disability Index, EuroQol-5D, and a visual analog scale for pain, which were completed preoperatively, and at three and six months following surgery.

Our study found that there was a statistically significant improvement in preoperative symptoms for the entire cohort ($p=0.001$). There were no cases of persistent dysphagia, vocal cord injury, or pseudoarthrosis (indicating failure of fusion) in any patients who have so far had the device implanted. Perhaps most importantly, there was no statistical difference in outcomes between patients undergoing multi-level discectomy surgery (in some cases up to four levels) and those patients who underwent surgery for a single level alone. This study has supported our adoption of zero-profile devices over plate fixation for all patients undergoing routine cervical discectomy surgery.

For more information on STALIF C, please contact Peter C. Gerszten, MD, MPH, or Erin E. Paschel, PA-C, at 412-647-1700.

Stereo-EEG for Diagnostic Epilepsy Surgery

by R. Mark Richardson, MD, PhD

Surgery is an effective therapeutic option for the treatment of pharmacoresistant epilepsy when the epileptogenic zone can be identified and removed. The epileptogenic zone is defined as the area of cortex that is necessary and sufficient for initiating seizures and whose removal is necessary for complete abolition of seizures. In many cases, the epileptogenic zone can be defined by a combination of noninvasive presurgical investigations such as video-EEG, 3T-MRI, PET, SPECT, and MEG. In cases of focal epilepsy where this data is not concordant (typically “MRI-negative” cases), identification of the epileptogenic zone requires the recording of seizures with electrodes placed intracranially.

Intracranial monitoring in American epilepsy centers typically has been performed by electrocorticography (ECoG), where electrodes are arranged in subdural grids and strips. These electrodes offer the possibility to record only from the brain surface, in contrast to intracerebral depth electrodes that enable direct recording from every cerebral structure. Depth electrodes may be used with the main goal of lateralizing seizures or with the more ambitious aim of defining the epileptogenic zone by stereo-electroencephalography (SEEG).

SEEG, developed by Talairach and Bancaud in Paris during the 1960s, involves recording electrophysiological signals via multiple depth electrodes and has been the intracranial monitoring procedure of choice in European epilepsy centers. SEEG offers advantages over surface-only recordings in cases where broad monitoring of lateral and mesial brain regions is indicated. Advances in high-resolution imaging, stereotactic planning software, and recording technology have created a growing clinical and scientific interest in SEEG, and our department recently initiated a formal program to bring this diagnostic option to epilepsy patients.

In our epilepsy center, patients being considered for intracranial monitoring are evaluated on a case-by-case basis

for ECoG or SEEG by our multidisciplinary epilepsy team. Since as many as 50% of patients who are thought to have bilateral seizure onset based on scalp EEG can be found to have unilateral seizure onset during intracranial monitoring, the use of bilateral depth electrode placement already has been standard in our program, when indicated. Now, in applying SEEG to select cases, precise recordings from lateral, mesial, and subcortical brain regions, including from multiple non-contiguous lobes, are being obtained without the need for performing a large craniotomy. With this technique, more than 10 electrodes can be placed in one hemisphere percutaneously, via skull-mounted anchor bolts.

We have found SEEG to be helpful in defining the epileptogenic zone in patients with non-lesional epilepsy, brain tumors, and recurrent seizures after previous resective epilepsy surgery. Importantly, SEEG successfully defines the epileptogenic zone in many patients who have previously been told they are not candidates for epilepsy surgery.

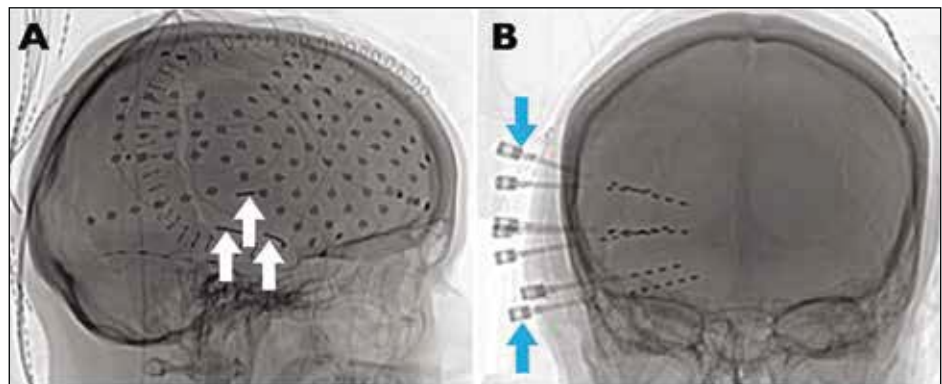


Figure 1. Intracranial monitoring for MRI-negative epilepsy. Depth electrodes may be placed during a craniotomy for grid and strip electrode placement (A, white arrows) or via skull-mounted anchor bolts (B, blue arrows) for SEEG.

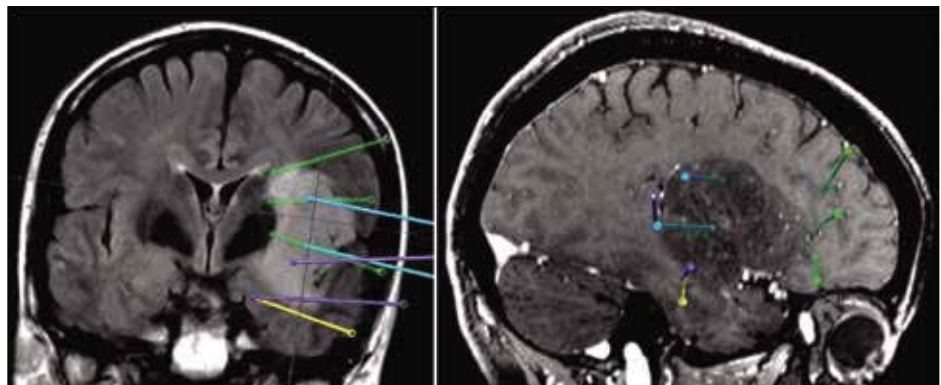


Figure 2. SEEG for brain tumor-related epilepsy. Images from SEEG surgical plans to delineate the epileptogenic zone in a patient with an insular glioma.

News & Notes

Gerszten Co-Edits Book on Stereotactic Radiosurgery



Peter C. Gerszten, MD, MPH, Peter E. Sheptak Professor of Neurological Surgery at the University of Pittsburgh, is co-editor of the newly released book *Controversies in Stereotactic Radiosurgery: Best Evidence Recommendations*, a 277-page look into an evidence-based approach to stereotactic radiosurgery for the brain and spine. Published by Thieme, the book is co-edited by Jason Sheehan, MD, professor of neurological surgery and co-director of the Gamma Knife Center at the University of Virginia.

Other contributors to the book from the University of Pittsburgh Department of Neurological Surgery include **L. Dade Lunsford, MD**, **Ajay Nirranjan, MD, MBA**, and **Edward A. Monaco III, MD, PhD**.

Okonkwo Part of New Major TBI Study



David Okonkwo, MD, PhD, associate professor of neurological surgery at the University of Pittsburgh and clinical director of the university's Brain Trauma Research Program, is one of a number of investigators from 20 institutions across the country taking part in a landmark \$18.8 million, five-year NIH study looking into better ways to diagnose and treat traumatic brain injury.

The study, coordinated by the University of California, San Francisco, is part of one of the largest international research collaborations ever coordinated by funding agencies. U.S. researchers are participating in the International Initiative for Traumatic Brain Injury Research (IntTBR), a collaborative effort of the European Commission, the Canadian Institutes of Health Research, the National Institutes of Health, and the U.S. Department of Defense.

Okada Presents Findings on Cancer Vaccine




Hideho Okada, MD, PhD, professor of neurological surgery, surgery, and immunology at the University of Pittsburgh and co-leader of the University of Pittsburgh Cancer Institute's Brain Tumor Program, presented findings of a brain cancer vaccine at the Fourth Quadrennial Meeting of the World Federation of Neuro-Oncology held in San Francisco this past November.

According to the study's findings, the vaccine—comprised of synthetic peptides and adjuvant poly:ICLC—was determined to be well-tolerated and induced specific and sustained immune responses against its brain tumor targets. Further, patients with a high magnitude of immunologic responsiveness experienced prolonged progression-free survival.

The synthetic peptide vaccine, developed by University of Pittsburgh researchers, had previously demonstrated single-agent clinical efficacy, including complete responses, in Phase 1/2 trials in both adults and children with high-grade glioma, including glioblastoma multiforme.

The study was supported generously by the National Institutes of Health (NIH), the Musella Foundation for Brain Tumor Research and Information, and the Voices Against Brain Cancer Foundation.

Maroon Completes Fifth Hawaiian Ironman



Joseph Maroon, MD, clinical professor of neurosurgery and Heindl Scholar in Neuroscience at the University of Pittsburgh, completed his fifth Hawaiian Ironman World Championship Triathlon on October 12 in Kona, Hawaii with a time of 16 hours, 3 minutes, and 48 seconds. Dr. Maroon's time placed him 15th in his age division (70-74) and 1,939th overall.

Thirumala Elected President of Pennsylvania Neurological Society



Parthasarathy D. Thirumala, MD, clinical assistant professor of neurological surgery and neurology and co-director of the UPMC Center of Clinical Neurophysiology, was elected president of the Pennsylvania Neurological Society at the group's annual meeting held in Philadelphia on October 10-12. Dr. Thirumala's term runs through 2015.

Foster Awarded Best Presentation at Rowe Day

PGY-6 resident **Kimberly A.**

Foster, MD, was awarded the best presentation award at the department's ninth annual Stuart Rowe Society Research and Lectureship Day on December 18, for her talk on "ABT-737 Synergizes with Vorinostat to Induce Apoptosis, Mediated by Noxa Upregulation, Bax Activation, and Mitochondrial Dysfunction in PTEN-Intact Malignant Human Glioma Cell Lines."

It was the third year in a row that Foster has received an award for a presentation at Rowe Day. In 2011 she also won for best presentation, while taking home the runner-up award in 2012.



David Panczykowski, MD, a PGY-3 resident, received the runner-up award this year for his presentation on "Glial Fibrillary Acidic Protein Breakdown Products for the Diagnosis of Intracranial Injury."

In the News

- **Dr. Maroon** was a guest on Sportsradio 93.7 The Fan (Pittsburgh) on November 7, commenting on news media reports regarding CTE, the brain disease that has been linked to repeated concussions and found in a number of former football players.
- **Robert Friedlander, MD**, was quoted in an October 7 Pittsburgh Post-Gazette article that reported on a \$100,000 grant from The Pittsburgh Foundation to the University of Pittsburgh School of Medicine. The grant will fund research into amyotrophic lateral sclerosis, the neurodegenerative disease also known as ALS or Lou Gehrig's disease.
- **Dr. Okonkwo** was noted in an October 22 Pittsburgh Post-Gazette article that cited his leading role in a major international study aimed at better understanding traumatic brain injury.

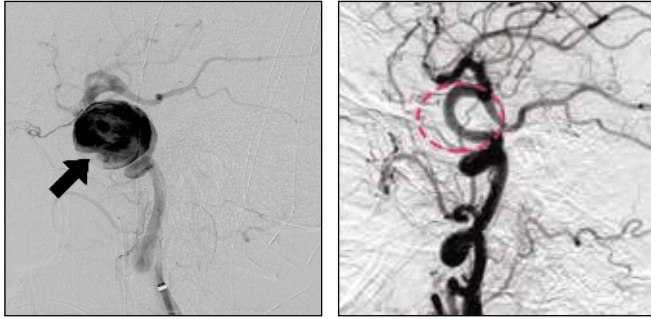


Figure 3. A giant cavernous carotid aneurysm (arrow) was successfully treated at UPMC by placement of a single Pipeline embolization device (left). At the six-month follow-up angiogram (right), the aneurysm was completely occluded. The dashed line indicates the anatomic location of the aneurysm prior to treatment.

complete and persistent coil occlusion, and represent a clear limitation of existing coil technology. For these aneurysms, endoluminal parent vessel reconstruction represents a significant conceptual advance. This is accomplished using a new generation of stent devices with increased metallic surface area and decreased pore density that function to divert flow away from the aneurysm.

The Pipeline® embolization device (Covidien) is a flow-diverting device that is specifically designed for use in the treatment of intracranial aneurysms. It is composed of 48 braided nitinol strands with a metal surface coverage of approximately 30%. FDA approval for the use of Pipeline was granted in May 2011 following completion of The Pipeline for Uncoilable or Failed Aneurysms trial. This pivotal trial included 108 patients with large (mean 18.2 mm) internal carotid aneurysms. Following Pipeline embolization, complete aneurysm occlusion was observed in 73.6% of patients at six months, with a relatively low rate of major complications (5.6%). These are impressive results, particularly given the size and anatomic complexity of these aneurysms. A rapidly growing number of case series have since been reported, which include a wide variety of aneurysm

locations and geometries. In general, the results are excellent, with high occlusion rates. Importantly, there has yet to be a report of an aneurysm initially occluded following flow diversion that went on to recanalize, thus eliminating perhaps the greatest limitation of coil embolization. As with other stents, however, Pipeline embolization necessitates dual anti-platelet therapy, which likely increases the risk of hemorrhagic complications and limits the use of Pipeline for ruptured aneurysms. In addition, a subset of patients does not respond adequately to clopidogrel and may thus be at elevated risk for thromboembolic complications. Platelet inhibition must therefore be carefully monitored and alternative antiplatelet regimens may be necessary.

Many questions regarding the use of these devices remain. While the majority of series involve placement of one or several overlapping devices across the neck of an aneurysm, some practitioners also place coils within the aneurysm in the hopes of promoting aneurysm occlusion. Whether such adjunctive coiling increases occlusion rates, and which aneurysms might benefit from this procedure, remain unanswered. Additionally, the appropriate frequency and timing of follow-up angiography and the benefit of repeat treatment remains unclear. Finally, while the device is currently approved for treatment of aneurysms of the internal carotid up to the superior hypophyseal segment, the indications for the use of flow diverters may ultimately be expanded. In the meantime, Pipeline embolization remains an attractive option that provides effective and durable occlusion for aneurysms that may otherwise be difficult to treat.

New flow-diverting devices such as Surpass (Stryker) and FRED™ (Microvention) are currently being evaluated in clinical trials, and refinements of existing devices continue. Clearly, the endovascular treatment of cerebral aneurysms is a continually evolving field. It is therefore critical that neuroendovascular practitioners remain abreast of these advances, in order to continue to offer the latest technologies and provide the best possible care for our patients.

Free Online CME

To receive CME credit, view this issue online at UPMCPHYSICIANRESOURCES.COM/NEUROSURGERY.

A world-renowned health care provider and insurer, Pittsburgh-based UPMC is inventing new models of accountable, cost-effective, patient-centered care. It provides more than \$887 million a year in benefits to its communities, including more care to the region's most vulnerable citizens than any other health care institution. The largest nongovernmental employer in Pennsylvania, UPMC integrates more than 62,000 employees, 22 hospitals, 400 doctors' offices and outpatient sites, a 2.2-million-member health insurance division, and international and commercial operations. Affiliated with the University of Pittsburgh Schools of the Health Sciences, UPMC ranks No. 10 in the prestigious *U.S. News & World Report* annual Honor Roll of America's Best Hospitals — and No. 1 in Pennsylvania. For more information, go to UPMC.COM.

UPMC is ranked among the nation's best hospitals by *U.S. News & World Report* and is ranked #8 nationally for neurology and neurosurgery. For more information about our programs, continuing medical education, Video Rounds, news, and events, please visit UPMCPHYSICIANRESOURCES.COM/NEUROSURGERY.

