Division of Vascular Surgery,
UPMC Heart and Vascular Institute

FALL 2017

In This Issue

VASCULAR ROUNDS

CME CREDIT

Instructions: To take the CME evaluation and receive credit, please visit http://www.upmcphysicianresources.com/heartandvascular, and click on *UPMC Vascular Rounds: Fall 2017*.

Accreditation Statement: The University of Pittsburgh School of Medicine is accredited by the Accreditation Council for Continuing Medical Education (ACCME) to provide continuing medical education for physicians. The University of Pittsburgh School of Medicine designates this enduring material for a maximum of .5 AMA PRA Category 1 Credits™. Each physician should only claim credit commensurate with the extent of their participation in the activity. Other health care professionals are awarded .05 continuing education units (CEU), which are equivalent to .5 contact hours. Disclosures: Drs. Abou Ali, Avgerinos, Eid, Leers, McEnaney, Mohapatra, Sachdev, Tillman, and Washington reported no significant relationships with proprietary entities producing health care goods or services. Dr. Singh serves on the CE Speakers' Bureau for Medtronic Venous.

Endovascular Therapy for Blunt Aortic Trauma

Michael J. Singh, MD, FACS, RPVI
Associate Professor of Surgery,
UPMC Division of Vascular Surgery

During the last two decades, endovascular therapy has revolutionized the way various aortic pathologies have been managed. Short- and mid-term data have shown benefits of utilizing this innovative therapy for aortic dissection, aneurysmal disease, and blunt aortic injury (BAI). Annually, more than 60 thoracic aortic endografts are implanted by UPMC vascular surgeons with excellent results.

Case Report

A healthy, physically fit 18-year-old wrestler was urgently transferred to UPMC as a level 1 trauma after falling from a seven-story building. After a quick trauma survey, the patient was taken for radiological studies. While in the CT scanner, he became hemodynamically unstable and was emergently taken to the operating room for exploratory laparotomy. The abdomen was explored and no active extravasation was observed so the abdomen was packed and other sources of hemodynamic instability were sought. A CT angiogram of the chest was performed and showed a complex aortic transection with mediastinal hematoma (Figures 1 and 2). The UPMC vascular surgery team urgently took the patient to the endovascular operating room. Percutaneous access of the right and left common femoral arteries was obtained. An arch aortogram was performed which located the BAI/aortic transection and relevant arch anatomy (Figure 3). A thoracic endograft was placed just distal to the left subclavian artery and completion imaging showed a successful repair (Figure 4). The femoral access sites were closed using percutaneous closure devices.

Discussion

Blunt aortic injuries, also known as aortic transection, are life-threatening injuries that are caused by rapid deceleration events. The incidence of blunt aortic injury (BAI) is estimated to be 1.5 to

(Continued on page 2)

Executive editor: Michel Makaroun, MD **Editor:** Karen Janosko **Assistant editor:** Mohammad Eslami, MD

Endovascular Therapy for Blunt Aortic Trauma (continued from page 1)

2 percent of all patients sustaining blunt thoracic trauma. The majority of injuries are due to motor vehicle collisions or falls from significant height. BAIs remain the second leading cause of death for individuals between the ages of four and 34, and most are men. It's estimated that more than 80 percent of patients expire prior to reaching an emergency room.

Anatomically, most BAIs are located at the aortic isthmus, just distal to the left subclavian artery, but they can occur in the ascending aorta or transverse arch. The aortic isthmus is a transition zone between the mobile ascending aorta and fixed descending aorta which makes it susceptible to dynamic stretch injuries. Typically, disruption of the intima and media occurs first followed by disruption of the adventitia and mediastinal pleura. Early identification of a BAI is crucial for patient survival. It is estimated that 30 percent of patients reaching a hospital with BAI fail to survive long enough to undergo repair.

The diagnosis of a BAI is suspected based on the mechanism of trauma. On trauma evaluation, significant chest and mediastinal injuries should alert the trauma surgeon of the likelihood of these injuries. But the diagnosis requires radiological studies. Plain chest films are routinely performed in the trauma area and may show signs of a possible aortic injury, including: a widened mediastinum, enlarged aortic knob, left apical cap, left hemothorax, displacement of the left main stem bronchus, upward deviation of the nasogastric tube, rightward tracheal deviation, or wide left paravertebral stripe. Imaging options which aid the diagnosis are transesophageal echocardiography (TEE) and computed tomography angiogram (CTA). Unstable patients should undergo TEE while in the operating room or at the bedside while stable patients should undergo a CTA, which is a highly sensitive and specific study for a BAI. Findings on chest CTA indicative of a BAI include: intimal flap, periaortic hematoma, luminal filling defect, pseudoaneurysm, contained aortic rupture, and active contrast extravasation.

An injury-specific approach should be used when determining the best treatment strategy for a BAI. This begins with intravenous access, IV fluid resuscitation, and antihypertensive therapy for patients with a systolic blood pressure greater than 100 mmHg (intravenous nitroglycerin or nitroprusside). In addition, intravenous esmolol can be used to achieve a goal heart rate of less than 100 beats per minute. The goal is to lower the systemic blood pressure and heart rate, which in turn stabilizes the extent of the aortic injury. Next, an expeditious patient transfer to a center of excellence that offers endovascular repair options is essential.

The surgical approach to a BAI depends on the hemodynamic status of the patient, severity of aortic injury, presence of additional injuries, and pre-existing medical conditions. Per Advanced Trauma Life Support guidelines, hemodynamically unstable patients should be emergently taken to the operating room for exploration to determine the source of bleeding. If the source of bleeding is identified as a BAI, immediate repair is required. If a BAI is identified, but life-threatening bleeding originates from another source, the aortic repair can be delayed to allow resuscitation and damage control. Various grading classifications for BAIs have been created based on the severity of aortic injury. One such scale aids in reporting and formulating treatment recommendations: type I – intimal tear, type II – intramural hematoma, type III – pseudoaneurysm, and type IV – aortic rupture (periaortic hematoma or free rupture). Contemporary studies suggest conservative management for type I – intimal injuries and delayed repair of type II and type III injuries in the face of multiple other life-threatening injuries. Immediate repair for all type IV injuries is expected.

Figure 1:
CT angiogram sagittal view type C blunt aortic injury/aortic transection (arrow).

Figure2:
CT angiogram cross sectional view of complex type C blunt aortic injury with mediastinal hematoma.

BAI repair can be performed with endovascular techniques or open surgical repair. Open repair requires a left thoracotomy, aortic cross clamping, left heart bypass, and aortic replacement using a prosthetic tube graft. In comparison, endovascular therapy (TEVAR) can be done percutaneously (via femoral artery access) with off-the-shelf devices in a relatively short period. The technique of TEVAR insertion is identical to that used for infrarenal aortic aneurysm endovascular repair. These procedures can be performed percutaneously or via small groin incisions and often without anticoagulation. The goal of endovascular treatment is to reline the aortic injury and control the hemorrhage. Currently, three TEVAR devices are approved for off-the-shelf use for the treatment of BIAs/aortic transections. These conformable off-the-shelf devices are readily available at UPMC facilities. Intuitively, avoidance of aortic cross clamping and systemic heparinization are advantageous in these patients who often present with polytrauma. For these reasons, endovascular repair has become the standard of care for treating BAIs. Several studies have shown improved 30-day outcomes for TEVAR over open aortic repair.

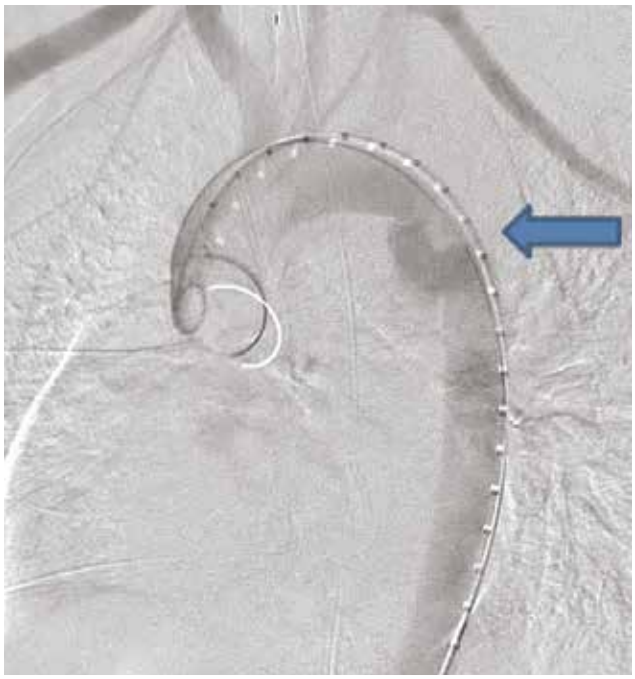

Figure 3:
Intraoperative arch angiogram showing blunt aortic trauma (arrow) and location of the great vessels.

The UPMC Division of Vascular Surgery is at the forefront of aortic trauma research and continues to participate in large multicenter randomized clinical trials focusing on the advancement of thoracic endograft technology (including branched endograft technology). Our vascular surgery team at the UPMC Heart and Vascular Institute continues to play an integral role in the development and advancement of cutting-edge technology by serving as one of a handful of sites in the United States for advanced aortic endograft trials. Our comprehensive patient care approach combined with technological advancements allows us to provide optimal care to patients with complex blunt aortic injuries.

Further Reading Suggestions

Rutherford's Vascular Surgery Textbook. 8th edition. Elsevier Saunders. Philadelphia, PA 2014

Demetriades D, Velmahos GC, Scalea TM, et al. Diagnosis and treatment of blunt thoracic aortic injuries: changing perspective. J Trauma 2008; 64: 1415

Azizzadeh A, Kehani K, Miller CC, et al. Blunt traumatic aortic injury; initial experience with endovascular repair. J Vasc Surg 2009; 49: 1403

Figure4:
Intraoperative arch angiogram after placement of the thoracic aortic endograft; covered graft segment starts distal to the left subclavian artery.

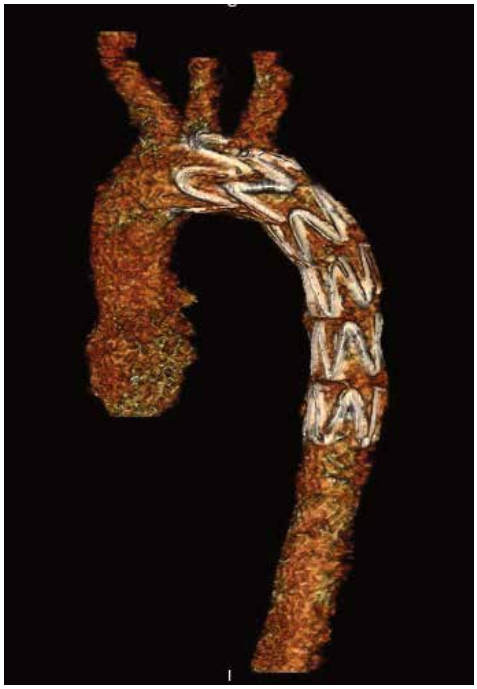

Figure5:
CT angiogram at six-month follow-up shows successful repair of the blunt aortic injury.

Shunting in Civilian Extremity Trauma: When and Where?

Efthymios D. Avgerinos, MD
Associate Professor of Surgery,
UPMC Division of Vascular Surgery

Adham N. Abou Ali, MD
Resident, UPMC Division of Vascular Surgery

Extremity vascular injury occurs at a rate of approximately 0.5 to 4 percent of trauma admissions and is associated with significant morbidity. Vascular trauma may occur because of iatrogenic, penetrating, or blunt injuries to the extremity. A current analysis of the National Trauma Databank (NTDB) showed that civilian amputation rates for upper and lower extremity arterial injuries are 1.3 percent and 7.8 percent, respectively.

Experience gained from military trauma showed that complex arterial and bone injuries of the lower extremities, due to high velocity projectiles, can lead to significantly high amputation rates. These amputation rates gradually have reduced due to the advancements of forward surgical facilities, rapidity of evacuation, and advances in blood replacement and shock management. In these advanced surgical units where the definitive vascular repair is not possible, use of temporary intravascular shunts (TIVS) has proved its superiority compared to ligation. These shunts maintain distal extremity perfusion prior to definitive arterial repair at another more equipped facility. As such, shunting has become the standard management in military arterial traumas with several case series and retrospective studies demonstrating its success. However, the same does not apply for civilian casualties and the use of shunts has not been universally adopted, despite its anticipated benefits.

Case Report

A 22-year-old man presented to the Emergency Department (ED) after sustaining a chainsaw injury to his right lower extremity (RLE). The injury occurred four hours prior to presentation to our hospital. There was profuse pulsatile bleeding from his medial knee/calf wound and the patient was hypotensive in the field. Paramedics applied a tourniquet to his right thigh which was still inflated when he arrived in the trauma bay. In the ED, he was awake and oriented but he could not move or feel his right foot distal to the injury. He had absent distal pulses and Doppler signals. He also had knee instability during orthopedic evaluation. As hypotension was persistent he was taken emergently to the operating room (OR) for wound exploration, debridement, and limb salvage by the trauma surgery team, which asked for the contribution of orthopedic, plastic, and vascular surgery services. On exploration, the patient had popliteal artery, popliteal vein (single), and tibial nerve transection. The leg was ischemic for five hours so immediate reperfusion was prioritized. Ten and 14 French Argyle shunts were placed in the popliteal artery and vein respectively

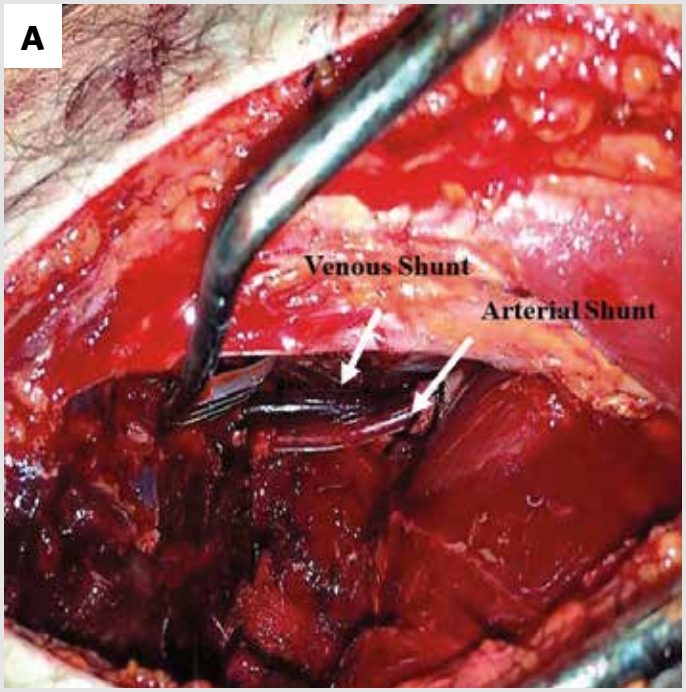

Figure 1A:
10F and 14F Argyle shunts placed in the popliteal artery and vein respectively.

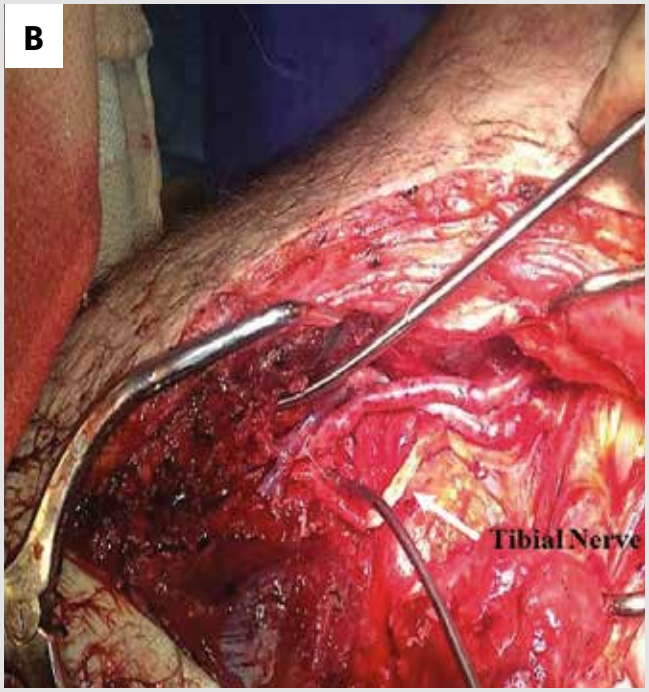

Figure 1B:
Great saphenous vein interposition for both popliteal artery and vein with tibial nerve reconstruction.

(Figure 1A) pending nerve reconstruction and orthopedic manipulation of the extremity. He subsequently recovered his triphasic posterior tibial artery signal and the foot got warm and pink; a DP signal was not identified. The orthopedic surgeons placed an external fixation and four compartment fasciotomies were performed. Given the patient's prolonged hypotension and pressor requirements, he was sent to the Intensive Care Unit for resuscitation. He returned to the operating room the next day to receive tibial nerve reconstruction by plastic surgery and a popliteal artery to tibioperoneal trunk saphenous vein interposition graft, as well as popliteal vein reconstruction again by an interposing saphenous graft (Figure 1B). The anterior tibial artery was transected and thrombosed, thus ligated at its origin. At three weeks' follow-up, the patient had no extremity pain. His wounds had completely healed. He had a palpable right posterior tibial pulse with adequate capillary refill and minimal foot edema. The patient had intact motor function at the level of his right knee and normal sensation down to the level of his foot. He had minimal motor function at the level of his right ankle and foot. He was cleared for weight bearing as tolerated soon after. He is undergoing extensive physical therapy on a well-perfused lower extremity.

Discussion

The largest and most recent multicenter U.S. study of civilian extremity trauma revealed that shunts are used in only 2.7 percent of vascular injuries. Two-thirds of the shunts were placed for damage control with the remaining one-third for combined orthopedic-vascular injuries. At UPMC the utilization rate of shunts is approximately 7 percent.

The high limb salvage and relatively low complication rates associated with shunts make them quite appealing. Even though data supporting shunt use is mostly retrospective, the data suggest that shunt use reduces fasciotomy, amputation, and reoperation rates. Trauma societal guidelines recommend minimizing the extremity ischemic time to less than six hours to allow for maximum limb salvage. Restoration of blood flow through temporary shunting is suggested in the presence of a concomitant bone injury, while immediate vascular repair is recommended for stable skeletal injuries. In contemporary practice, temporary intravascular shunting is indicated in (1) open extremity fractures with extensive soft tissue injury and concurrent arterial injury (Gustilo IIIC, Table), (2) the need for perfusion during complex vascular reconstruction, (3) damage control for patients in extremis, (4) perfusion prior to limb replantation, (5) truncal vascular control, and (6) complex repair of zone III neck injuries.

The most commonly shunted extremity vessels are the superficial femoral artery (25 percent) and the popliteal artery (19 percent). Proximally placed shunts have a superior patency compared to distal shunts given that distal arteries are more prone to vasospasm under shock conditions. Although no differences among shunt types have been reported, the Argyle shunt (C.R. Bard, Inc., Billerica, Mass.) followed by the Pruitt-Inahara shunts (LeMaitre Vascular, Inc., Burlington, Mass.) have been the most commonly utilized conduits by the UPMC Division of Vascular Surgery. Shunt diameter is of critical significance; oversizing causes intimal injury while under sizing might cause shunt thrombosis or dislodgement. Current shunt configuration is in a straight position (vs. looped) inserted to a depth of 2cm into the injured vessel.

Yet, shunts may not always be benign adjuncts. There are reports of shunts increasing the risk of graft failure through endothelial injury particularly if they are used off-label (e.g., chest and feeding tubes) and if the shunt is oversized. Shunt dislodgement should also be expected in approximately 1.5 percent of cases. Multidisciplinary management and appropriate vascular expertise is of outmost importance for optimal outcomes. Intravascular shunts, carefully used and appropriately sized can significantly mitigate adverse outcomes after extremity vascular injuries.

Further Reading Suggestions

Subramanian A, Vercruysse G, Dente C, Wyrzykowski A, King E, Feliciano DV. A decade's experience with temporary intravascular shunts at a civilian level I trauma center. J Trauma (2008) 65(2):316–24; discussion 324–6. doi:10.1097/TA.0b013e31817e5132

Abou Ali AN, Salem KM, Alarcon LH, Bauza G, Pikoulis E, Chaer RA et al. Vascular Shunts in Civilian Trauma. Front Surg. (2017) 4:39. doi:10.3389/fsurg.2017.00039

Tan TW, Joglar FL, Hamburg NM, Eberhardt RT, Shaw PM, Rybin D, et al. Limb outcome and mortality in lower and upper extremity arterial injury: a comparison using the National Trauma Data Bank. Vasc Endovascular Surg (2011) 45(7):592–7. doi:10.1177/1538574411415125

Inaba K, Aksoy H, Seamon MJ, Marks JA, Duchesne J, Schroll R, et al. Multicenter evaluation of temporary intravascular shunt use in vascular trauma. J Trauma Acute Care Surg (2016) 80(3):359–65. doi:10.1097/TA.0000000000000949

Table: Gustilo Classification of Open Fractures

Classification of Open Fractures	Description
Type I	• Puncture wound of < 1 cm with minimal soft tissue injury • Minimal wound contamination or muscle crushing
Type II	• Wound > 1 cm in length • Moderate soft-tissue injury • Comminution is minimal
Type IIIa	• Extensive soft tissue damage • Includes massively contaminated or segmental fractures • Soft tissue coverage of the bone is adequate
Type IIIb	• Extensive soft tissue damage with periosteal stripping and bone exposure • Usually severely contaminated and comminuted • Flap coverage is required to provide soft tissue coverage
Type IIIc	• Associated with an arterial injury requiring repair for limb salvage

Pediatric Vascular Trauma

Ulka Sachdev, MD
Associate Professor of Surgery, UPMC Division of Vascular Surgery

Christopher Washington, MD
Clinical Assistant Professor of Surgery, UPMC Division of Vascular Surgery

Abhisekh Mohapatra, MD
Vascular Surgery Resident

Pediatric trauma is the leading cause of death in children older than one year in the United States. Although vascular injuries are infrequent, occurring in 0.6 to 1 percent of trauma patients, they constitute an important cause of mortality in children after trauma. The spectrum of treatment choices for vascular injuries includes expectant therapy, vessel ligation, direct vessel repair, or interposition graft repair.

Case Report 1

A 9-year-old boy presented to Children's Hospital of Pittsburgh of UPMC two hours after inadvertently pushing his right arm through a glass door. According to the paramedics there was substantial blood loss at the scene. Upon evaluation in the emergency room he was hemodynamically stable and there was no active bleeding or pulsatile hematoma. There was a large wound with protruding biceps muscle belly in the right upper extremity above the level of the elbow. The patient had weak Doppler signals in the radial and ulnar arteries. His neurovascular exam was notable for mild weakness in the hand along with a slight sensory deficit at the tips of his fingers. Given the absence of distal pulses and presence of a neurosensory deficit the patient was taken urgently to the operating room for exploration of the wound.

Upon exploration of the wound there was evidence of a brachial artery transection with thrombosis of the proximal end. The proximal and distal ends of the artery were separated by five centimeters necessitating an interposition reversed saphenous vein graft. Further exploration identified a transection of the median nerve. The plastic surgery service then performed a nerve graft repair of the median nerve along with closure of the wound (Figure 1). At the conclusion of the procedure the patient had a palpable radial pulse. He was discharged home on postoperative day two.

Case Report 2

A second 9-year-old boy presented to Children's Hospital of Pittsburgh of UPMC after falling from a boat and sustaining a penetrating injury to his distal right thigh from the propeller. There was significant blood loss at the scene necessitating tourniquet placement by paramedics. On evaluation in the emergency department, he had a large posterior tissue defect in the popliteal fossa with the distal femur at the base of the wound (Figure 2). He was unable to dorsiflex or plantarflex his right ankle. With the tourniquet in place, the wound was hemostatic. He was taken emergently to the operating room for wound exploration.

Initial exploration of the wound revealed complete transection of the popliteal artery, paired popliteal veins, and the tibial and peroneal nerves. Though there was a large soft tissue defect, there was minimal separation of the ends of the artery and veins. After mobilization of the popliteal vessels, proximal and distal control were obtained the tourniquet was released. One popliteal vein was repaired primarily and the other ligated. Thrombectomy catheters were passed proximally and distally into the artery with brisk inflow and back bleeding achieved, and the artery was repaired primarily. Excellent Doppler signals were audible in the popliteal artery and vein and the pedal arteries. However, after completion of four-compartment calf fasciotomies, the pedal signals were no longer audible. Suspecting technical error, the anastomosis was revised, and again after a brief period of patency the pedal signals were lost. An on-table angiogram was performed, which showed occlusion just distal to the patent anastomotic site. The anastomosis was re-opened and additional thrombus was retrieved. Using the great saphenous vein from the contralateral limb, a 2-cm segment of the popliteal artery was resected and replaced with an interposition graft. Signals returned at that time, and remained audible during exploration of the nerve injury by the plastic surgery service. He was taken to the ICU at that time with DP and PT signals. The next morning, he had a palpable DP pulse and the foot was warm. He returned to the operating room with plastic surgery for cadaveric nerve graft repairs, and underwent serial washouts and eventual closure of the wound and his fasciotomy sites. He was discharged on postoperative day 14 and is doing well with physical therapy.

Overview

Pediatric vascular injuries are often due to penetrating trauma and male gender and occur more frequently in the upper extremities. It is difficult to standardize the management of pediatric patients with vascular injuries due to a diverse set of factors. First, these vascular injuries are rare, occurring in less than 0.6 percent of pediatric patients who present with trauma. Additionally, many different specialties participate in repair of these injuries ranging from pediatric surgeons, adult trauma and/or vascular surgeons, orthopaedic surgeons, and neurosurgeons to plastic surgeons. Each specialty group brings their unique perspective and background in how to deal with these injuries which makes arriving at a consensus difficult. Furthermore, pediatric vascular injuries are far more technically challenging to treat and this adds significant complexity to the choice of treatment for these injuries. The unique issues with these patients include the size (diameter) of the injured vessel and spasticity of young vessels, and the choice of treatment must accommodate ongoing axial growth in this pediatric population. It is possible to apply the same principals and techniques of adult trauma to older children but younger children may require different approaches. In pediatric patients with vascular injuries, historically, definitive arterial reconstruction has not always been the preferred management approach. Ligation or expectant therapy (systemic heparin without repair) was the most common choice of treatment. Adverse outcomes such as loss of axial growth leading to debilitating gait disturbances, limb overgrowth due to traumatic arterio-venous fistula, and amputation have prompted calls for a more aggressive

approach in management of pediatric extremity vascular injuries. The presence of hard signs of vascular injuries including ischemia, active pulsatile bleeding, or expanding hematoma mandate urgent surgical intervention.

When repairing pediatric arterial injuries there are a number of factors to take into consideration. It is recommended that interrupted suture repairs are used rather than running suture repairs as they allow for vessel growth. Also there are relative contraindications to using PTFE in pediatric patients secondary to long term patency concerns. Pediatric vessels are more prone to spasm than adult vessels. The use of papavarine can be beneficial in breaking this spasm. Finally, there is increasing evidence that traumatic injuries in the pediatric population induce a temporary hypercoagulable state, which, together with small vessel size and spasm, can significantly hinder the ability to maintain vessel patency in the acute setting. The treatment of these injuries often requires the expertise of multiple specialties including pediatric trauma surgeons, hand surgeons, and vascular surgeons.

References

Kirkilas M, Notrica D, Langlais C, Muenzer J. Outcomes of arterial vascular trauma in pediatric patients. Journal of Pediatric Surgery. 2016;51:1885-1890.

Leeper CM, Neal MD, McKenna CJ, Gaines BA. Trending Fibrinolytic Dysregulation: Fibrinolysis Shutdown in the Days After Injury Is Associated With Poor Outcome in Severely Injured Children. Annals of Surgery. 2017;3:508-515.

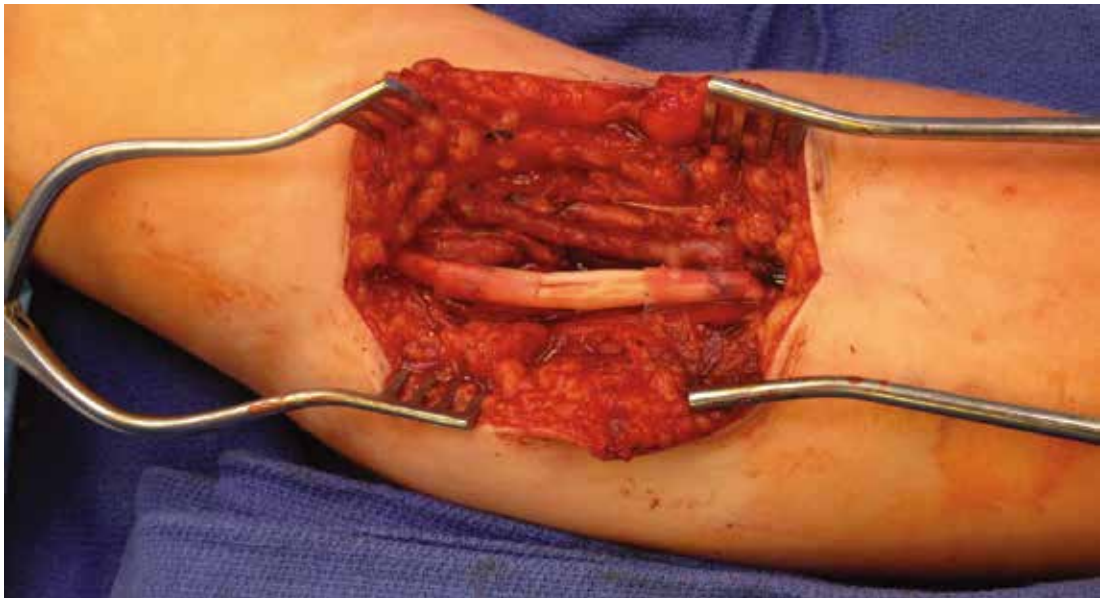

Figure 1:
Picture demonstrating saphenous vein interposition graft of the brachial artery with nerve grafting of the median nerve.

Figure 2:
Injury to the popliteal fossa from a boat propeller (patient's head to the right) with extensive soft tissue injury and transection of the popliteal artery and veins and sciatic nerve branches.

Research Spotlight

A RESCUE Stent for Non-Compressible Traumatic Hemorrhage

Bryan Tillman, MD, PhD
Assistant Professor,
UPMC Division of Vascular Surgery

Non-compressible hemorrhage from the torso from aortic and caval injuries remain a significant dilemma in trauma with poor outcomes. Although many patients may expire in the prehospital phase, for those that do arrive to a trauma bay, the initial "golden minutes" are critical for rapid control of exsanguination. Open repair is hindered by challenging and time consuming exposure in a blood-submerged operative field. Conversely, although permanent aortic or caval stent repair is within the means of most major trauma centers, mobilizing endovascular expertise, imaging, and inventory are frequently not available within the critically short window of exsanguinating hemorrhage. These challenges are magnified when the exact location of the injury may be unknown.

While balloon occlusion of the aorta has been introduced to mitigate massive hemorrhage, the approach presents several limitations, including ongoing retrograde bleeding, cessation of blood flow to critical organs, and in the case of caval balloon occlusion, loss of critical venous return to the heart. As a result, the risk of complications from balloon occlusion could be significant outside of select patients with injuries confined to the pelvis.

As part of a Department of Defense-funded study, the UPMC Division of Vascular Surgery designed a "petal and stem" stent design that may address many of these challenges (Figure 1). The RESCUE stent approach would allow rapid intravascular tamponade of an injury while maintaining distal flow and avoidance of the logistical challenges of permanent stent graft repair (Figure 2) and these include:

- **Flexible sizing:** Contrasting to the often-fixed diameter of permanent stents, the "petal and stem" design accommodates to a wide range of vessel diameters and eliminates the need for prior imaging or time-consuming sizing in the emergency setting of massive hemorrhage. The radial force of conventional stents so critical in permanent repair is thereby replaced by a fixed "stem" that prevents stent migration.

Figure 1

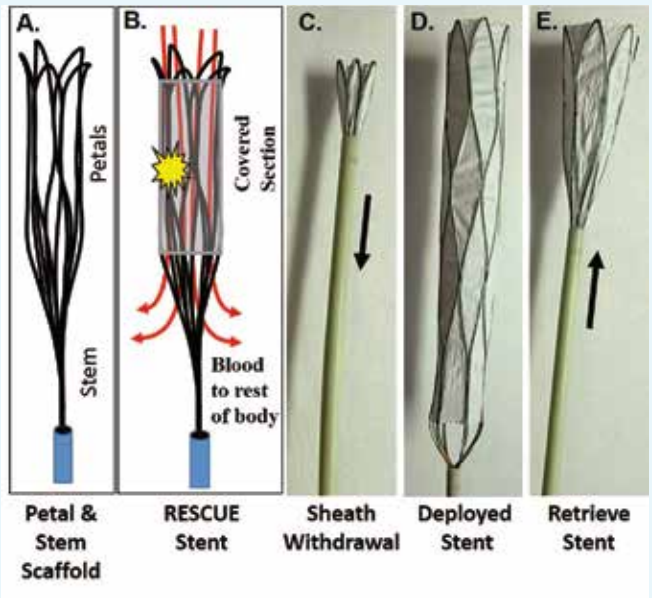

Figure 2

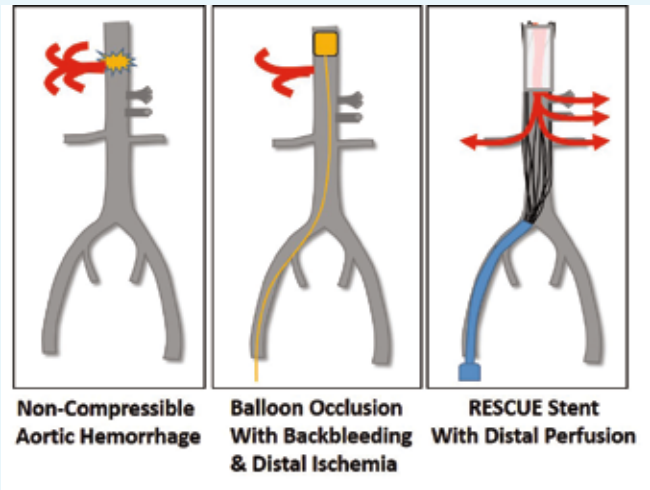

- **Percutaneous delivery:** The surgical morbidity of open vascular exposure, especially during trauma, is compounded by a blood-filled operative field and increased risks for surgical contamination. The RESCUE stent offers percutaneous delivery similar to conventional stents, thereby reducing the sterile field needed for acute hemorrhage control. The required step of arterial line placement is a skill set well known to the trauma team. Currently the venous RESCUE stent is 9 French while the aortic stent is 8 French.
- **Distal perfusion:** Contrasting to balloon occlusion which poses risks of ischemic injury by obstruction of distal perfusion, the stent design offers continued flow of blood beyond the site of injury (Angiography of a Caval RESCUE stent in Figure 3).
- **Placement without the need for fluoroscopy:** Fluoroscopy represents a cornerstone of modern endovascular interventions. In an emergency setting, however, fluoroscopy is bulky, requires experienced operators, and presents radiation hazards to other members of the trauma team. To meet this challenge, we are replacing fluoroscopy with a radiofrequency signaling approach. Radiofrequency (RF) signals are widely used for wireless identification of domestic animals and even for detection of retained surgical sponges. By use of external palpable landmarks such as the xiphoid or clavicle as a reference point for key vascular branches (visceral and subclavian arteries, respectively), an external radiofrequency detector can track the RF tagged stent as it is passed from the groin to the thoracic or abdominal aorta, while avoiding key vascular branches (Figure 4). This becomes practical since the young demographic of trauma patients are essentially free of occlusions and other vascular pathology that would otherwise obligate more detailed imaging. A vascular morphometry study is currently underway to match external landmarks to vascular branches as well as optimal lengths for the RESCUE stent.

The RESCUE stent may offer the trauma team a means to acutely control exsanguinating aortic or caval hemorrhage until the patient can be transported (either between hospitals or within a hospital) to environments with the proper equipment, expertise, and inventory for proper vascular repair. Much work remains as we optimize this approach for the variability that is inherent among patients. In summary, with further refinement, the RESCUE stent may become an important tool in the management of life-threatening non-compressible hemorrhage from trauma and iatrogenic injuries.

RF Figure:

Retrievable Design: The most important feature of the RESCUE stent is the retrievable design. This ensures the stent can be placed rapidly under less than ideal circumstances yet does not obligate the patient to potential long term complications of permanent stent graft of entire vessel segments. A more durable and precise repair can then be undertaken in the proper environment upon removal of the RESCUE stent. Removal is achieved by simple sheath advancement once the actual injury is repaired (Figure 1).

Figure 3

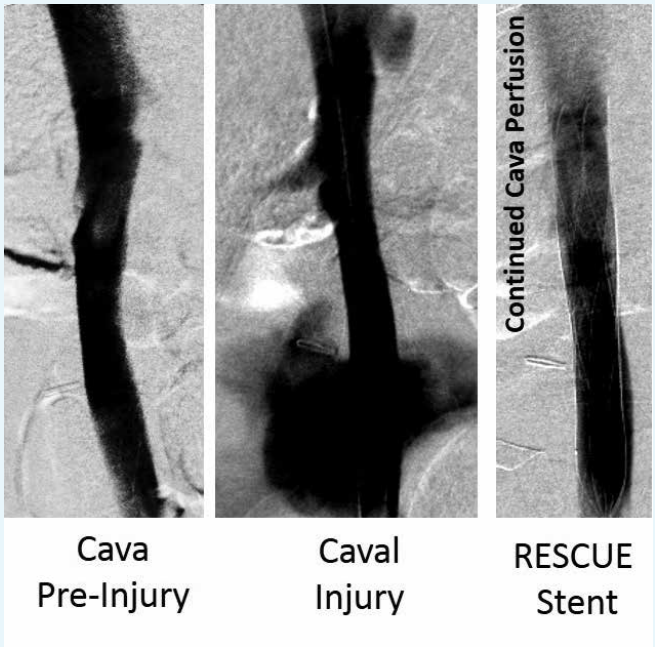

Figure 4

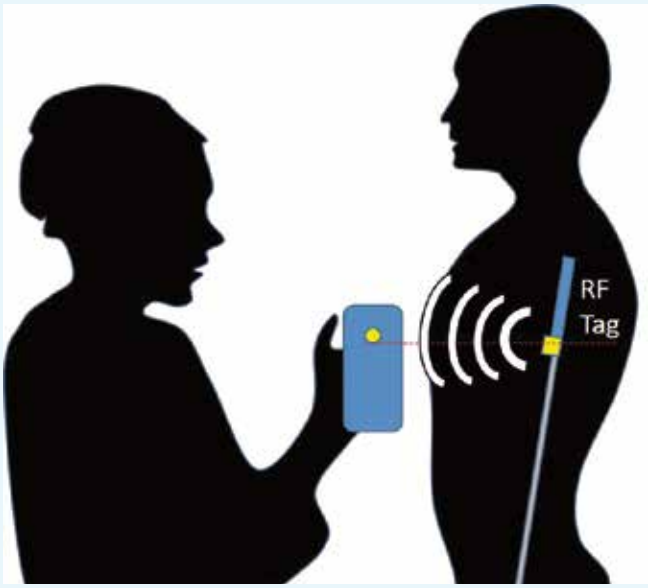

Traumatic Innominate Artery Injury

Raymond E. Eid, MD
Assistant Professor of Surgery,
UPMC Division of Vascular Surgery

Steven A. Leers, MD
Associate Professor of Surgery,
UPMC Division of Vascular Surgery

Injury to the innominate artery accounts for approximately half of the great vessels injuries, with the subclavian and left common carotid arteries accounting for almost all the remainder. Pulmonary vessels, azygous vein, and thoracic caval injuries are quite rare. The true incidence of innominate artery injury is underestimated as most victims die prior to arriving at the hospital. Excluding aortic trauma, blunt injury to the thoracic great vessels is infrequent and presents several challenges to the treating physicians and surgeons.

Case Report

A 19-year-old unrestrained male driver who was involved in a head-on motor vehicle accident at high speed was seen in the emergency room of our level 1 trauma medical center. On initial evaluation, he was found to be hypotensive, tachycardic, and complaining of abdominal pain. A FAST examination was positive and he was taken emergently to the operating room for an exploratory laparotomy. A grade IV liver laceration was found and this was repaired by the trauma surgeon. Postoperatively, completion imaging to rule out other injuries was done. This showed a large 2.6 cm pseudoaneurysm of the innominate artery close to the takeoff of the carotid artery with associated mediastinal hematoma (Figure 1 A). He subsequently underwent an aortic arch angiogram to better delineate the injury (Figure 1 B). This injury was not amenable to endovascular intervention so he was taken to the operating room for open repair of the innominate artery. Through a median sternotomy, the chest cavity was entered. The aortic arch and the innominate artery were identified, and the artery was dissected to its bifurcation into the right subclavian and carotid artery (Figure 2A). After vascular control, the pseudoaneurysm was opened and the innominate artery injury was identified (Figure 2B). The linear tear was clean and for that reason, the decision was made to repair the artery primarily instead of replacing it with a bypass graft (Figure 2C). The patient tolerated the procedure well. His postoperative course was uneventful and he was discharged home on postoperative day nine.

Discussion

Injury to the thoracic great vessels can be one of the most challenging surgical problems for the treating surgeons. These injuries can occur secondary to blunt or penetrating mechanisms. Blunt thoracic aortic and great vessels injuries are the second most common cause of trauma- related death after head injury. Mortality from blunt trauma to the thoracic great vessels can be as high as 54 percent. Associated extra-thoracic injuries, especially abdominal and cerebral, are common and contribute to the high morbidity and mortality.

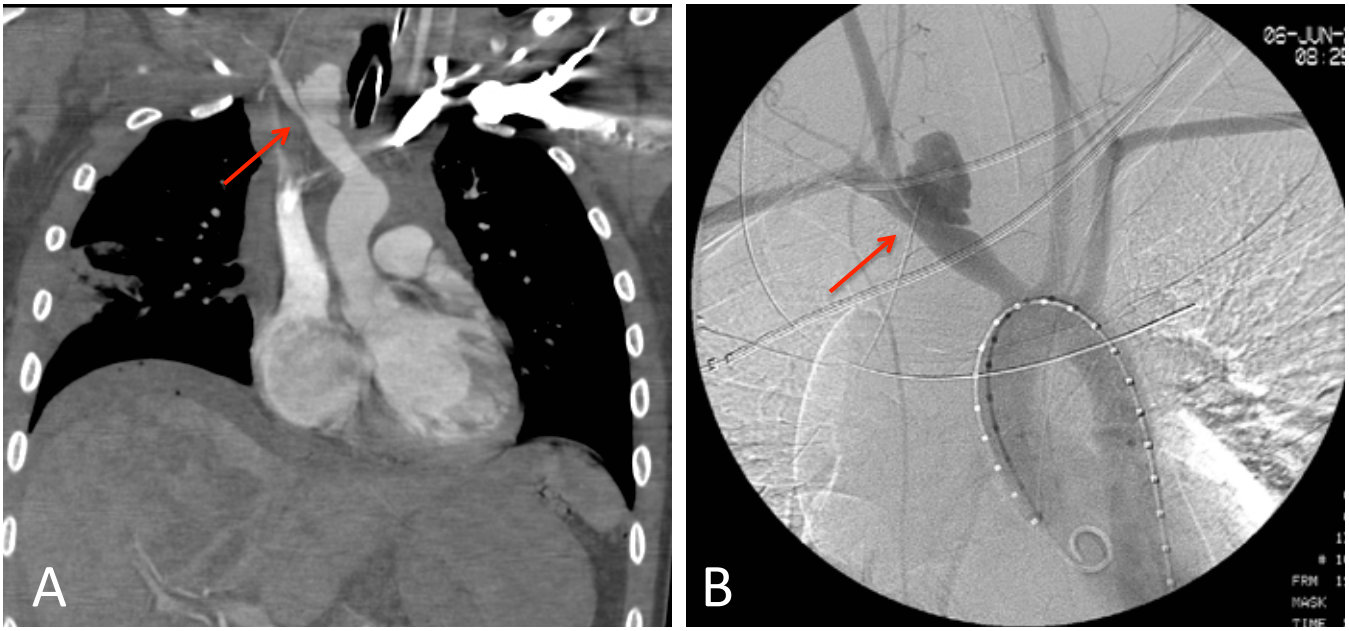

Figure 1
CT angiogram (A) and diagnostic angiogram (B) showing the innominate artery pseudoaneurysm.

Mechanism of Injury

Injury to the thoracic great vessels is often associated with high-speed motor vehicle collision (>60 miles per hour). These patients often have high injury severity scores, and these injuries often have other significant associated injuries. Most occur after head-on collisions (72 percent) compared to side (24 percent) or rear impact collisions (4 percent).

Blunt thoracic great vessels injury is thought to occur after sudden deceleration leading to hyperextension and traction on blood vessels leading to vessel wall disruption, occlusion, or avulsion. A small intimal tear can lead to thrombus formation and occlusion, while more significant injuries such as disruption or avulsion may lead to pseudoaneurysm formation or free rupture and death.

Evaluation and Imagining

The clinical picture of patients with blunt arch vessel injuries varies from asymptomatic to profound shock. On admission, most patients are hemodynamically stable, have extra-thoracic injuries, may or may not have signs of limb ischemia, and often have a brachial plexus injury. The vascular physical examination findings are often not very sensitive but diminished or absent pulses should alert the examiner of the possibility of this type of injury. Conversely, the presence of a pulse does not exclude an arterial injury since there is an excellent collateral flow around the shoulder. Additionally, hemispheric neurological findings may alert the clinician to possible injuries to the innominate or carotid arteries.

A portable chest x-ray provides essential information as it may demonstrate pneumothorax, hemothorax, rib fractures, or a widened mediastinum. Mediastinal widening is the most common radiographic finding with blunt great vessel injury and warrants further investigation. An abnormal chest radiograph, especially a widened mediastinum, should prompt further imaging to precisely define the location and extent of the vascular injury. With the advancement of computed tomography and its wide availability, CT angiography has become the diagnostic test of choice.

Treatment

Definitive treatment is performed through an open or an endovascular approach. Unstable patients require immediate operation. Among stable patients, treatment options include operative management and endovascular intervention. This decision depends on the specific anatomy and availability of specialized personnel. Several incisions have been used to obtain exposure of the great vessels, with median sternotomy with clavicular or neck extension providing an optimal exposure for most great vessel trauma. Most injuries, especially blunt, will require prosthetic graft interposition due to the degree of vessel injury and contusion, and less commonly, the injury is amenable to autologous vein patch or primary repair. While most traumatic aortic injuries are now managed with an endovascular approach, this technique is more limited in the management of the aortic branch injuries due to anatomical limitations. Although these injures are associated with significant mortality and morbidity, rapid diagnosis and prompt intervention can yield gratifying results.

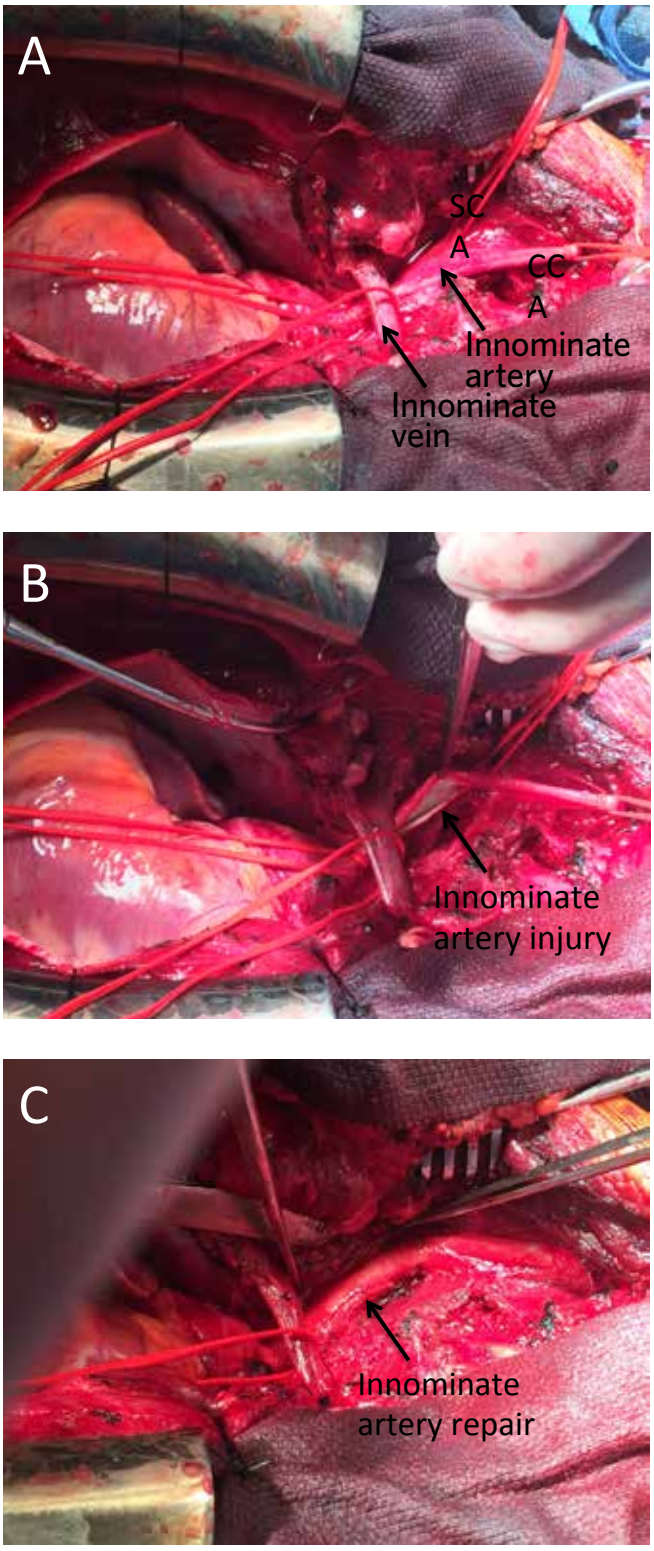

Figure 2

Embolization of Arterial Injuries

Ryan McEnaney, MD
Assistant Professor of Surgery,
UPMC Division of Vascular Surgery

Blunt trauma can cause arterial injuries in the pelvis and extremities indirectly by laceration from bone fragments. Arterial injuries may also be the results of atrogenic injury at the time of orthopedic repair. The following cases represent endovascular treatment of arterial injuries that presented in delayed fashion after an orthopedic surgery.

Case Report 1

A 93-year-old female had fallen and suffered an oblique spiral fracture of her right femur. This was repaired by open reduction and internal fixation utilizing a locking plate, a cable, and numerous screws. She underwent an uneventful postoperative recovery in the hospital and was transitioned to inpatient physical rehabilitation. However, three weeks after the repair, the patient began to experience rapidly worsening right thigh pain. Pain worsened over a period of 24 hours. She presented to the emergency department with a pulsatile thigh mass, anemia requiring blood transfusion, and excruciating pain. A CT arteriogram was performed and demonstrated a large pseudoaneurysm (Figure 1A) measuring approximately 8 cm in diameter in the thigh associated with the mid-femur repair. Although the scan was limited by the large amount of metal hardware in the right lower extremity, the pseudoaneurysm appeared to originate from the distal part of the profundal femoral artery.

Given the patient's age, comorbidities, and an anatomically challenging location of the bleeding, a percutaneous option to control the bleeding was preferable. An arteriogram demonstrated that the distal right profundal femoral artery appeared to be injured between the cable and the first femoral screw opposite the locking plate, where a large active pseudoaneurysm with a large active chamber was identified (Figures 1B, 1C). Importantly, the distal profundal could also be identified filling from the injured artery. Using a microcatheter the distal profundal was carefully sub-selected, and the distal end of the injured artery was successfully accessed. Coil embolization using micro coils occluded the arterial segments on both sides of the injury, resolving the pseudoaneurysm (Figures 1D, 1E). The thigh mass was no longer pulsatile and her thigh pain had completely resolved. She recovered well and was discharged uneventfully to continue rehabilitation. At one month follow-up she remained pain-free in the thigh and her thigh mass had reduced in size substantially.

Case Report 2

A 73-year-old male had fallen from a ladder and suffered multiple traumatic injuries including a pelvic fracture. The pelvic fracture was addressed at an outside hospital using a long sacral screw placed through a left lateral gluteal incision. Three weeks after the surgery, he had been suffering from severe left gluteal and hip pain, tenderness, and swelling. The patient was found to be extremely tender over his left hip and gluteal region and very tense to palpation. A contrasted CT scan was performed which demonstrated a contrast blush in the region of the screw in the ileum (Figure 2A). Again, severe artifact from the metal screw prevented precise localization of the contrast blush, but appeared to be likely related to a branch of the superior gluteal artery.

An arteriogram was performed which verified a contrast blush appearing near the head of the sacral screw, (Figure 2B) originating from a branch of the superior gluteal artery. A microcatheter was then used to access this branch vessel and a sub-selective arteriogram of the pseudoaneurysm was performed. The downstream part of this artery beyond the pseudoaneurysm was occluded and there was no outflow vessel identified. In essence, the pseudoaneurysm was a blind end to this arterial branch. The active chamber was then coiled using microcoils and the feeding vessel was similarly coiled completely excluding the pseudoaneurysm (Figure 2C). A final arteriogram demonstrated that flow through the pelvis and

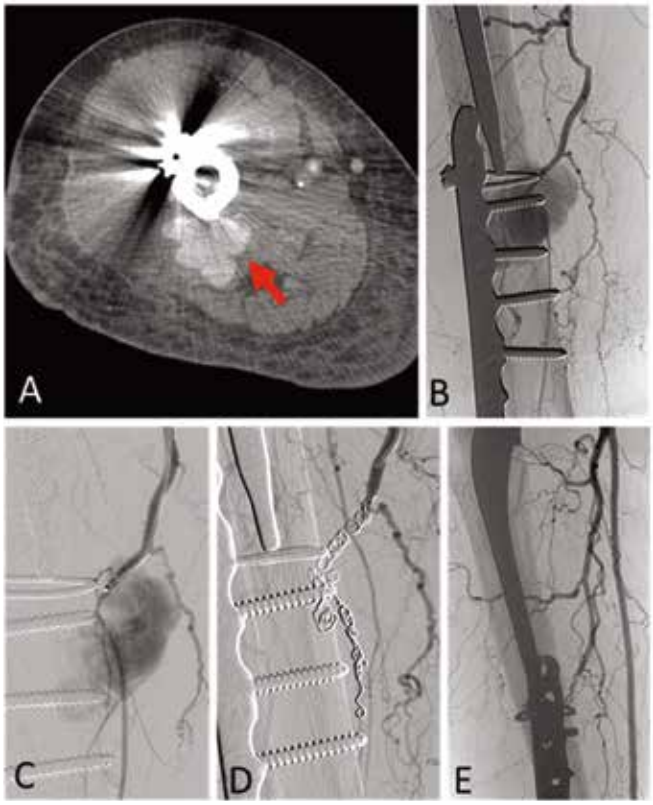

Figure 1:
Latrogenic pseudoaneurysm originating from the profundal femoral artery.
A) CT image demonstrating the large contrast blush in the mid-thigh the origin of which is obscured by artifact created from the plate (red arrow).
B, C) Initial and sub-selective arteriogram identifies the inflow and outflow of the pseudoaneurysm is the distal profundal femoral artery.
D) Coil embolization was performed of the inflow and outflow resulting in resolution of the pseudoaneurysm (E).

gluteal arteries was preserved and that there was successful occlusion of the branch of the superior gluteal artery (Figure 2D). Immediately post procedure, the patient reported complete resolution of left hip pain. The patient had done well postoperatively recovering without further incident and did not require hematoma evacuation. The follow-up CT scan demonstrated that the pseudoaneurysm was occluded and the hematoma was reduced in size substantially.

Discussion

Pelvic arterial injury after blunt injury is relatively common after major motor vehicle accidents with injuries involving the pelvis. These injuries have been traditionally treated by pelvic immobilization. Ongoing bleeding of these injuries may lead to significant hemodynamic abnormality and open treatment of such injuries are significantly morbid. The mechanisms of these injuries are thought to be either from direct blunt force injury to these vessels, or injury sustained due to fractured bone fragments. These injuries can also develop from iatrogenic injury following internal fixation of a fracture[1, 2]. Depending on the size and the depth of the arterial injury, clinical presentations may include ongoing bleeding, a tense mass or swelling with or without pulsatile quality, or an expanding pseduoaneurysm. These are typically associated with pain, but also may be complicated by hemorrhage and anemia, nerve compression or compartment syndrome, and even rupture with hemodynamic instability[3-5]. Several management strategies for such arterial injuries or pseudoaneurysms have been reported in the literature, and involve some form of intervention to prevent ongoing bleeding or progressive pseduoaneurysm enlargement and consequences from compression and potential bleeding. Arterial injuries can be treated by open ligation or stent graft coverage of the injured vessel. Interventions for pseudoaneurysms originating from these small branch vessels include thrombin injection if accessible, open surgical interventions, or coil embolization[2, 5-7].

In both presented cases, the presentation with swelling, pain, and anemia occurred in a delayed fashion approximately three weeks after the initial trauma and orthopedic repair. Fortunately, these patients did not have neurological compromise and embolization adequately relieved muscular compression. Clinicians must be alert that if compartment syndrome or neurological compromise is present, then surgical hematoma evacuation or decompression must accompany the vascular embolization. Advances in endovascular technology more and more allow for less complicated and safer treatment of these type of injuries with much faster postoperative recovery.

References

1. Barquet A, Gelink A, and Giannoudis PV. Proximal femoral fractures and vascular injuries in adults: Incidence, aetiology and outcomes. Injury. 2015;46(12):2297-313.
2. Craxford S, Gale M, and Lammin K. Arterial Injury to the Profunda Femoris Artery following Internal Fixation of a Neck of Femur Fracture with a Compression Hip Screw. Case reports in orthopedics. 2013;2013(181293.
3. Ge PS, Ng G, Ishaque BM, Gelabert H, and de Virgilio C. Iatrogenic pseudoaneurysm of the superior gluteal artery presenting as pelvic mass with foot drop and sciatica: case report and review of literature. Vascular and endovascular surgery. 2010;44(1):64-8.
4. Roth JS, and Newman EC. Gluteal compartment syndrome and sciatica after bone marrow biopsy: a case report and review of the literature. The American surgeon. 2002;68(9):791-4.
5. Corbacioglu KS, Aksel G, and Yildiz A. Ruptured superior gluteal artery pseudoaneurysm with hemorrhagic shock: Case report. Turkish journal of emergency medicine. 2016;16(1):26-8.
6. Griselli F, Calvagna C, Sgorlon G, Zamolo F, D'Oria M, Chiarandini S, and Adovasio R. Management of an Iatrogenic Pseudoaneurysm of the Superior Gluteal Artery by Percutaneous Ultrasound-Guided Thrombin Injection: A Case Report. Annals of vascular surgery. 2017;38(317.e9-.e11.
7. Spratt JR, Bretzman PA, Lafferty PM, and McGonigal MD. Gluteal Compartment Syndrome: Successful Management with Combined Angioembolization and Surgical Decompression. Minnesota medicine. 2016;99(3):51-2.

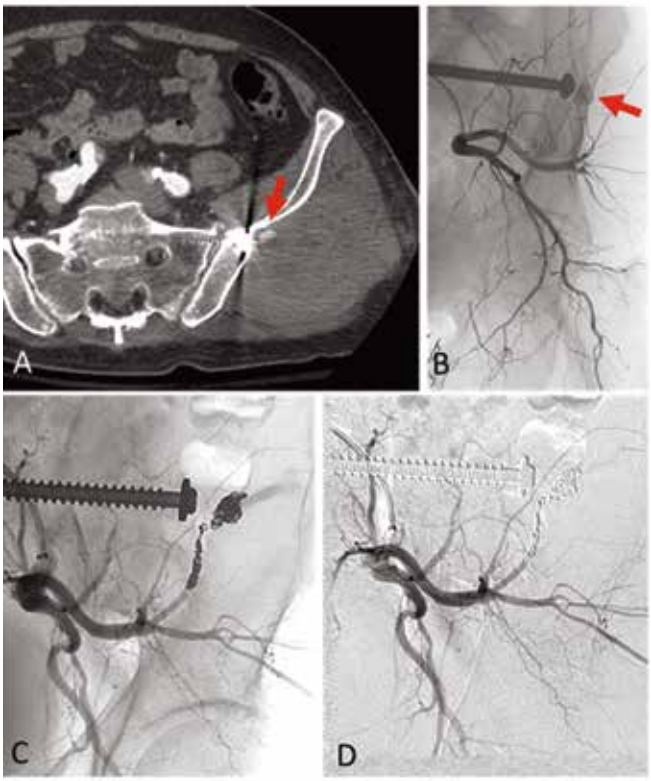

Figure 2:
Latrogenic pseudoaneurysm originating from the superior gluteal artery.
A) CT image demonstrating a small contrast blush (red arrow) associated with a large gluteal hematoma, again somewhat obscured by the associated sacral screw. B) Arteriogram identified the active pseudoaneurysm (red arrow) originating from a branch of the superior gluteal artery. C) Coil embolization was performed of the active chamber and the feeding artery. No outflow vessel could be identified on subselective arteriogram. D) Digital subtraction arteriography demonstrates successful occlusion without any residual flow into the pseudoaneurysm.

Department News

Michel Makaroun, MD, Named President-Elect of Society of Vascular Surgery

Michel S. Makaroun, MD, chief of the Division of Vascular Surgery and co-director of the UPMC Heart and Vascular Institute, was named president-elect of the Society for Vascular Surgery at its annual meeting in June. He will serve in this role for one year, then ascend to president in June, 2018.

Dr. Makaroun has been active in the SVS since 1997 and served as secretary from 2013-2016. Dr. Makaroun received his medical degree from the American University of Beirut, where he also completed a surgical internship and residency program, before coming to the University of Pittsburgh for a fellowship in vascular surgery.

Dr. Makaroun is certified by the American Board of Surgery in surgery, with a certificate of special qualification in vascular surgery, and has a primary interest in the endovascular and surgical repair of abdominal aortic aneurysms. He is extensively published, presenting his research at conferences around the world. Dr. Makaroun has been with the University of Pittsburgh School of Medicine and UPMC for more than 30 years.

Theresa Cole, DO, Joins UPMC Division of Vascular Surgery

Theresa Cole, DO, joined the UPMC Division of Vascular Surgery in 2017. She earned her medical degree from Lake Erie College of Osteopathic Medicine and completed her osteopathic internship and general surgery residency at Conemaugh Memorial Medical Center in Johnstown, Pa., followed by a fellowship in vascular surgery at the Greenville Hospital Systems University Medical Center in Greenville, SC.

Dr. Cole is a clinical assistant professor of surgery and is board-certified in surgery and vascular surgery. Her clinical practice includes open surgical and endovascular treatment of aneurysms, interventions for carotid disease, and care for patients with peripheral vascular disease. She sees patients at Washington Hospital through the UPMC Heart and Vascular Institute's partnership with Washington Health System and at our Monongahela office.

Bryan Tillman, MD, PhD, Receives Grant from National Institutes of Health

Bryan W. Tillman, MD, PhD, assistant professor, UPMC Division of Vascular Surgery, and Youngjae Chun, PhD, assistant professor, University of Pittsburgh Swanson School of Engineering, were awarded a four-year, $1.3 million R01 grant from the National Institutes of Health entitled "An Organ Perfusion Stent as an Alternative to Surgery in Donor Organ Recovery."

Recognizing the critical shortage of donor organs available for transplantation and the large number of organs discarded as a result of damage from poor perfusion, Dr. Tillman's team designed a Dual Chamber Organ Perfusion Stent. The objectives of the grant are to demonstrate that the dual chamber and retrievable stent design will improve perfusion of the isolated abdominal organs, while respecting key ethical considerations of the organ donor. Eventually, this technology may allow organs which might have been otherwise damaged to be protected and increase the number of lifesaving organs available for transplant. Other collaborators include Sung Kwon Cho, PhD, and William C. Clark, PhD , of the Swanson School of Engineering, Ryan Dzadony, CCP, LP, of Procirca®, and Anthony J. Demetris, MD, and Amit Tevar, MD of the Thomas E. Starzl Transplantation Institute.

Save the Date
Thursday, May 24 to Saturday, May 26, 2018

15th Annual Pittsburgh Vascular Symposium

To help celebrate our fifteenth conference, we welcome the **Surgical and Radiological Endovascular Symposium** from France to Pittsburgh for this meeting.

This course will provide evaluation and critique of the current and future standards of care in the treatment of the vascular patient with respect to medical management, as well as endovascular and open therapies for the primary care provider, cardiologists, interventionalists, and the vascular surgeon. It continues to focus on new developments in technology, as well as surgical techniques, and will highlight the controversies and accepted practices.

This course is designed for primary care providers, cardiologists, interventionalists, vascular surgeons, and other interested health care professionals who provide primary care services.

Registration details are coming soon! For more information, please contact Mark Byrne at **byrneme@upmc.edu**.

UPMC
LIFE CHANGING MEDICINE
200 Lothrop St.
Pittsburgh, PA 15213-2582

FACULTY LISTING

***Vascular Rounds* is published for heart and vascular professionals by UPMC.**

Executive editor:
Michel Makaroun, MD

Assistant editor:
Mohammad Eslami, MD

Address correspondence to:

Karen Janosko
Division of Vascular Surgery
UPMC Presbyterian, Suite A-1011
200 Lothrop St.
Pittsburgh, PA 15213-2582

For additional information concerning *Vascular Rounds*, or to suggest future topics, contact Karen Janosko at janoskokm@upmc.edu or call 412-802-3333.

Division of Vascular Surgery
UPMC Heart and Vascular Institute
UPMC Presbyterian, Suite A-1011
200 Lothrop Street
Pittsburgh, PA 15213-2582

About UPMC

A $16 billion world-renowned health care provider and insurer, Pittsburgh-based UPMC is inventing new models of patient-centered, cost-effective, accountable care. UPMC provides more than $900 million a year in benefits to its communities, including more care to the region's most vulnerable citizens than any other health care institution. The largest nongovernmental employer in Pennsylvania, UPMC integrates 80,000 employees, more than 30 hospitals, 600 doctors' offices and outpatient sites, and a 3.2 million-member Insurance Services Division, the largest medical insurer in western Pennsylvania. As UPMC works in close collaboration with the University of Pittsburgh Schools of the Health Sciences, *U.S. News & World Report* consistently ranks UPMC on its annual Honor Roll of America's Best Hospitals. UPMC Enterprises functions as the innovation and commercialization arm of UPMC, and UPMC International provides hands-on health care and management services with partners on four continents. For more information, go to UPMC.com.