

# UPMC RENAL GRAND ROUNDS

FALL 2017



## Renal Toxicity Related to Immune Checkpoint Inhibitors

### ERIC ONG, MD

*Fellow, Renal-Electrolyte Division  
Department of Medicine  
University of Pittsburgh School of Medicine*

### HELBERT RONDON-BERRIOS, MD, FACP, FASN

*Assistant Professor, Renal-Electrolyte Division  
Department of Medicine  
University of Pittsburgh School of Medicine*

#### Accreditation Statement

The University of Pittsburgh School of Medicine is accredited by the Accreditation Council for Continuing Medical Education (ACCME) to provide continuing medical education for physicians.

The University of Pittsburgh School of Medicine designates this enduring material for a maximum of .5 AMA PRA Category 1 Credits™. Each physician should only claim credit commensurate with the extent of their participation in the activity. Other health care professionals are awarded .05 continuing education units (CEU), which are equivalent to .5 contact hours.

#### Disclosures

Drs. Ong and Rondon-Berrios report no relationships with proprietary entities producing health care goods and services.

#### Instructions

To take the CME evaluation and receive credit, please visit [UPMCPhysicianResources.com/Kidney](http://UPMCPhysicianResources.com/Kidney) and click on the course Renal Grand Rounds Fall 2017.

Affiliated with the University of Pittsburgh School of Medicine, UPMC is ranked among the nation's best hospitals by *U.S. News & World Report*.

### Introduction

As early as the 18th century, physicians noticed that some cancer patients went into remission after developing fevers from infections. This led to the idea that the immune system, which protects from infection, might also fight cancer. What is now known as “immunotherapy” is a treatment that targets the immune system to recognize and eradicate cancer cells. Modern immunotherapy has focused on “checkpoint” proteins, such as cytotoxic T-lymphocyte-associated-protein-4 (CTLA-4) and programmed death-1 protein (PD-1), which are receptors on the surface of immune cells that act like a brake, or checkpoint, preventing the development of autoimmunity.<sup>1</sup> The CTLA-4 receptor has homology to the T-cell activator co-stimulatory molecule CD28 and prevents T-cell activation by outcompeting CD28 for its ligand, the B7 receptor on antigen presenting cells (APCs).<sup>2</sup> Likewise, binding of PD-1 with programmed death ligand 1 (PD-L1) — a protein expressed by immune, endothelial, and neoplastic cells — results in T-cell anergy.<sup>3</sup> In both cases, an unwanted inflammatory response is suppressed.

**Contacts and Referrals:** For consults and referrals, please call UPMC's 24-hour physician OnDemand service at 1-866-884-8579.

**UPMC**  
LIFE CHANGING MEDICINE

Tumors can evade immune surveillance, however, by co-opting these checkpoints. PD-L1, for example, is overexpressed across several cancer cell types. The end result is the inactivation of T cells infiltrating the tumor, thereby avoiding cancer cell death.<sup>1</sup> This discovery has led to the emergence of a novel type of immunotherapy — immune checkpoint inhibitors (CPIs) — which are monoclonal antibodies that target inhibitory proteins such as CTLA-4, PD-1, and PD-L1.<sup>4</sup> In essence, CPIs enhance tumor killing by blunting the braking mechanism that blocks T-cell activation, thereby augmenting the patient's immune response. CPIs are currently considered among the most innovative and promising agents in the treatment of cancer.<sup>5,6</sup>

Four CPIs are currently approved by the FDA — ipilimumab, nivolumab, pembrolizumab, and atezolizumab — to treat melanoma, lung, renal, bladder, lymphoma, and head and neck cancers. Ipilimumab, a CTLA-4 inhibitor, was the first agent to enter the market with FDA approval in 2011. It drastically changed the landscape for melanoma treatment, extending overall survival in patients with unresectable stage III and IV melanoma.<sup>7,8</sup>

By the end of 2014, nivolumab and pembrolizumab, both PD-1 inhibitors, also were approved. Nivolumab now is used as a first-line treatment for unresectable or metastatic melanoma in combination with ipilimumab if the cancer does not have a BRAF mutation.<sup>9</sup> Nivolumab also has been shown to be effective in the second-line setting in patients with advanced renal cell carcinoma, as well as non-small cell lung cancer (NSCLC) that has progressed during or after platinum-based chemotherapy.<sup>10,11</sup> Pembrolizumab is now the first immunotherapy to be approved for first-line use in metastatic NSCLC if the cancer overexpresses PD-L1.<sup>12</sup> It also has indications in the treatment of metastatic melanoma and head and neck squamous cell carcinoma.<sup>13,14</sup>

The most recent CPI to be introduced is atezolizumab, which blocks PD-L1. Atezolizumab was recently granted accelerated

approval by the FDA for use in advanced urothelial carcinoma that has progressed on platinum-containing regimens.<sup>15,16</sup>

This represents a significant milestone in urothelial cancers after a void of more than 30 years. While the role of immunotherapy was first established in nonmuscle invasive bladder cancer in the 1970s, no systemic immunotherapy was approved for advanced disease until atezolizumab.

New indications for CPIs are being approved on a regular basis, and as their use has increased, so too has the incidence of their unique side effects — termed immune-related adverse events.<sup>17,18</sup> Their pathophysiology is still not fully understood but may be similar to that of autoimmune disease, wherein activated lymphocytes target self-antigens.<sup>19</sup> The most specific immune-related adverse events of ipilimumab are colitis and endocrinologic complications (hypothyroidism and hypophysitis); adverse events associated with pembrolizumab and nivolumab are pneumonitis and hypothyroidism.<sup>20</sup> This review will focus on renal immune-related adverse events related to the use of ipilimumab, nivolumab, and pembrolizumab, as well as combination therapy. Acute kidney injury (AKI) is the most commonly reported event, followed by hyponatremia.<sup>21</sup> It is likely that nephrologists will increasingly have to diagnose and manage these side effects as the use of CPIs continues to expand.

### Case Report

A 59-year-old man with a history of hypertension and metastatic renal cell carcinoma (RCC) of clear cell type was admitted with a 3-week history of intermittent fevers. RCC had been diagnosed 5 months prior, and he had already failed treatment with pazopanib, a tyrosine kinase inhibitor. Three weeks prior to presentation, he had been started on second-line treatment with a PD-1 inhibitor, nivolumab 0.3 mg/kg. Blood and urine cultures, as well as a chest x-ray, were negative from when he had seen his oncologist 5 days prior. Review of systems was negative for any localizing symptoms of infection. Home medications did not include any antibiotics,

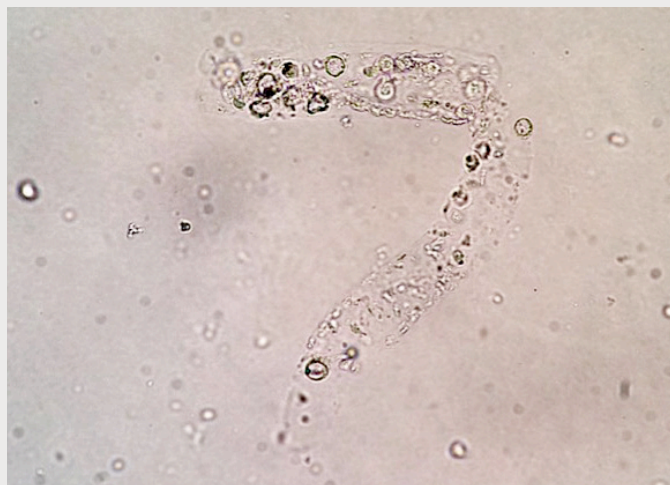
NSAIDs, or proton pump inhibitors. On physical examination, the patient was afebrile, with a blood pressure of 118/74 mmHg, a pulse of 89 bpm, and oxygen saturation of 95% on room air. Lungs were clear to auscultation bilaterally. Precordial exam revealed a regular rhythm and normal heart sounds, without murmurs or rubs. The abdomen was soft and nontender, with a palpable mass on the right side. Back exam revealed no costovertebral angle tenderness. He had no focal neurological deficits. Skin exam revealed no rash. He had trace edema in his lower extremities bilaterally. Laboratory results were notable for an elevated serum creatinine of 2.8 mg/dL. This peaked to 4.0 mg/dL 3 days later despite aggressive volume expansion. His serum creatinine was 0.9 mg/dL when measured 3 weeks prior at the time of his first nivolumab dose. No peripheral eosinophilia was present, but urinalysis revealed 2+ protein, 8 WBC/hpf, and 9 RBC/hpf. Ultrasound revealed a known right kidney mass measuring 12.5 cm x 13.1 cm x 2.6 cm, associated with mild right hydronephrosis.

Nephrology was consulted to address the patient's AKI. It was thought unlikely to be due to unilateral hydronephrosis, and the patient was diagnosed with acute tubulointerstitial nephritis (ATIN) secondary to nivolumab exposure. He was started on solumedrol (80 mg IV the first day, 50 mg IV daily thereafter) 3 days after admission, when serum creatinine was 4.0 mg/dL. Six days later, creatinine had fallen to 3.09 mg/dL, and the patient was discharged on prednisone 60 mg PO daily.

The patient was seen in our nephrology clinic 9 days after discharge, and his creatinine was noted to have further improved to 2.56 mg/dL. Of note, his urine sediment exam at this time revealed numerous WBC casts (Figure 1). The patient completed a prednisone taper over the next 4 weeks and was noted to have near full recovery to a creatinine of 1.09 mg/dL, measured 33 days after the initiation of steroids. His oncologist rechallenged him with nivolumab at this time, and creatinine measurements thereafter increased to a new

baseline of 1.3 mg/dL. The patient also started experiencing intermittent fevers again and was briefly admitted for pneumonitis. Prednisone was restarted at a maintenance dose of 10 mg PO daily, but ultimately nivolumab was discontinued due to ongoing adverse effects resulting in noncompliance. He has since been started on cabozantinib, another tyrosine kinase inhibitor.

**Figure 1:** Urine Microscopy Examination.



### Incidence

Despite not being very common, CPI-induced renal toxicity causes excess morbidity and, in some cases, treatment discontinuation. Cortazar et al. analyzed data from all published phase II and III clinical trials that included at least 100 patients treated with CPIs. The overall incidence of AKI was 2.2% among a total combined analysis of 3,695 patients. AKI occurred more frequently in patients who received combination therapy with ipilimumab and nivolumab (4.9%) than in patients who received monotherapy with ipilimumab (2.0%), nivolumab (1.9%), or pembrolizumab (1.4%). The incidence of grade III or IV AKI, defined as an increase in creatinine > 3-fold above baseline, an increase in creatinine to a level > 4.0 mg/dL, or the need for renal replacement therapy, was 0.6%.<sup>22</sup> This data suggests that AKI is a relatively scarce event with the use of CPIs.

A recent meta-analysis analyzed eight randomized clinical trials involving CPIs, amounting to a total of 4,070 patients. All grade immune-related renal toxicity ranged from 0.7% to 6%, while high-grade immune-related renal toxicity ranged from 0% to 2%. The findings also showed that compared with chemotherapy control (docetaxel and dacarbazine), the four evaluated immune checkpoint inhibitors (ipilimumab, nivolumab, pembrolizumab, and ipilimumab/nivolumab combination) carried a higher risk of all-grade renal toxicity.<sup>23</sup>

### **Ipilimumab**

Since CTLA-4 is expressed on virtually all T cells, ipilimumab has the potential to induce immune-related adverse events in a wide variety of tissues and organs. Cases of difficult-to-treat or even fatal side effects have been reported, including sarcoidosis, Guillain-Barré syndrome, and drug reaction with eosinophilia and systemic symptoms (DRESS).<sup>24-26</sup> Notably, it was the first CPI recognized to be associated with kidney disease.

The first case described of ipilimumab-induced AKI involved the development of an immune-complex-mediated glomerulonephritis. A patient with metastatic melanoma was treated with ipilimumab and developed nephrotic syndrome after two injections. Circulating anti-double-stranded DNA antibodies appeared concomitantly but regressed 3 months after ipilimumab was discontinued. Renal biopsy was suggestive of lupus nephritis.<sup>27</sup> A separate case of nephrotic syndrome in the form of minimal change disease (MCD) also has been reported.<sup>28</sup>

More common, however, are cases of acute tubulointerstitial nephritis (ATIN), as was seen in the initial clinical trials.<sup>26,27,29-31</sup> The first reported case of ipilimumab-induced ATIN after FDA approval was not biopsy-proven, but renal function improved rapidly with steroid therapy — highly suggestive of an immune phenomenon.<sup>30</sup> Seven cases of ipilimumab-associated ATIN were subsequently reported in the literature and recently reviewed by Izzedine et al.<sup>26,27,30-33</sup>

Most patients presented with AKI and subnephrotic range proteinuria 6 to 12 weeks after initiation of ipilimumab.

The largest case series of biopsy-proven ATIN related to CPI administration was reported by Cortazar et al. Pathology revealed ATIN to be the primary pathology in 12 of 13 patients who developed AKI while on CPI therapy. In those taking ipilimumab monotherapy ( $n = 6$ ), ATIN occurred 3 to 35 weeks following the start of treatment. CPIs were discontinued in all patients because of AKI, except for one who remained on ipilimumab monotherapy and never recovered renal function. Glucocorticoids were given to 10 of the 12 patients with ATIN, and nine had complete ( $n = 2$ ) or partial ( $n = 7$ ) renal recovery. The two patients treated conservatively had no recovery and became dialysis dependent. Steroids were tapered over 4 to 12 weeks in a majority of the cases. Interestingly, eight patients were also taking medications commonly associated with ATIN.<sup>22</sup>

### **Nivolumab**

AKI was reported in most of the nivolumab trials in patients with melanoma.<sup>34-40</sup> A recent meta-analysis suggests, though, that ipilimumab monotherapy carries a higher risk of all-grade renal toxicity compared to nivolumab monotherapy.<sup>23</sup> Shirali et al. recently published six cases of biopsy-proven ATIN following CPI therapy for lung cancer. Three were treated with nivolumab monotherapy, and all had discontinuation of their therapy due to AKI. Biopsies showed diffuse ATIN. The delay between nivolumab initiation and development of ATIN was 40 to 64 weeks, much later than what was seen with ipilimumab. All except one patient received glucocorticoid therapy as a 4-week taper, and notably, all recovered renal function to or near baseline. The one patient not treated with steroids was continued on nivolumab for the next 8 months and recovered to baseline creatinine after 6 months. Like the Cortazar et al. study, several of the patients were taking medications known to cause ATIN before starting CPI therapy: five out of the six

patients were taking proton pump inhibitors (PPIs), while two of the three on nivolumab monotherapy were taking nonsteroidal anti-inflammatory drugs (NSAIDs).<sup>41</sup>

### Pembrolizumab

A recent meta-analysis has found pembrolizumab to carry a higher risk of all-grade renal toxicity than either ipilimumab or nivolumab monotherapies, though this was not consistent with the analysis by Cortazar et al.<sup>23</sup> To date, there have been four reported cases of biopsy-proven ATIN attributed to pembrolizumab. The time from pembrolizumab initiation to ATIN onset was between 4 to 54 weeks. Three patients responded to steroids with complete remission, while one patient required dialysis and had partial remission with steroids. The duration of steroid taper varied from 4 to 12 weeks. Of note, one of the patients receiving pembrolizumab initially achieved partial renal recovery with CPI and PPI discontinuation, as well as a 4-week steroid taper. Two weeks after completing the taper, however, serum creatinine worsened dramatically. The patient reported resuming omeprazole therapy in the meantime. Prednisone was restarted and tapered over a 12-week period.<sup>22,41</sup>

Yet another report on pembrolizumab details the development of AKI due to rhabdomyolysis. After failing treatment with ipilimumab and an alkylating agent, temozolomide, a patient with advanced mucosal melanoma developed lung and spinal metastases. He was started on anti-PD-1 therapy with pembrolizumab 43 weeks later, and upon presentation prior to the sixth dose, he complained of myalgia and was found to have a creatine kinase (CK) of > 30,000 units per liter (reference range 55-170). AKI subsequently developed despite aggressive volume expansion. Further laboratory testing revealed a thyroid-stimulating hormone (TSH) of 187 mIU per liter (reference range 0.5-5) with undetectable free thyroxine. Normalization of thyroid function tests (TFTs) with just thyroxine replacement was accompanied by normalization of his CK.<sup>42</sup> Thyroiditis is a well-established

side effect of CTLA-4 blockade. In fact, recommendation for TFTs before each ipilimumab infusion are included in the ipilimumab package insert.

### Ipilimumab and Nivolumab Combination

The combination of two checkpoint inhibitors, ipilimumab and nivolumab, was approved by the FDA in 2015 as a first-line treatment in metastatic melanoma.<sup>38</sup> The major limiting factor of using these agents together is a high level of toxicities. A recent study of ipilimumab and nivolumab combination therapy for melanoma showed higher rates of severe adverse events (Common Terminology Criteria for Adverse Events grade 3 or 4) for dual therapy (55%) compared with ipilimumab or nivolumab alone (27% and 16.3%, respectively). However, severe renal toxicity (grade 3 or 4 adverse events) was still relatively rare in the combination group, though there was a clear stepwise increase in the risk of developing AKI: 3 out of 313 (0.9%) patients on nivolumab, 8 out of 311 (2.5%) on ipilimumab, and 17 out of 313 (5%) on combination therapy.<sup>38</sup> In support of this, a recent meta-analysis noted that for all-grade renal toxicity, the ipilimumab/nivolumab combination still carried a higher risk than either ipilimumab or nivolumab monotherapies. No statistically significant difference in all-grade renal toxicity was detected between pembrolizumab and ipilimumab/nivolumab combination.<sup>23</sup>

Overall, there are six reported cases of biopsy-proven ATIN due to combination therapy for melanoma treatment.<sup>22,39,41</sup> Biopsies have shown either focal or diffuse ATIN, as well as more granulomatous ATIN compared to other CPIs. Time to ATIN onset in these cases ranged from 5 to 33 weeks. In the Shirali et al. case series, one of the patients receiving combination therapy responded initially to CPI withdrawal and solumedrol pulse followed by daily prednisone, but 2 weeks later developed worsening serum creatinine, necessitating the addition of mycophenolate mofetil (MMF) and an increase in prednisone dose. Only one of the six cases reported so far achieved complete renal recovery with glucocorticoid therapy.

## Mechanisms of Injury

Although the mechanism of CPI-induced ATIN is not completely understood, it is speculated that there are two possible mechanisms. First, as the CTLA-4 and PD-1 pathways normally operate to limit autoimmunity, interference with these pathways can lead to unwanted immune effects. This is supported by murine models, wherein CTLA-4 knockout mice develop diffuse lymphocytic invasion in multiple tissues and die at 3 to 4 weeks of age.<sup>43,44</sup> Comparable findings have also been found in human studies.<sup>45,46</sup> Specific to the kidney, PD-1 signaling limits CD8-positive T-cell-mediated inflammatory injury, and PD-1 knockout mice spontaneously develop interstitial nephritis and a lupus-like glomerulonephritis.<sup>47,48</sup> Similar findings were observed in mice treated with an anti-PD-1 monoclonal antibody, supporting the importance of PD-1 signaling in minimizing T-cell-mediated renal inflammation.<sup>49</sup> Thus, CPI-induced ATIN may be due to the loss of tolerance against endogenous kidney antigens, as opposed to the delayed-type hypersensitivity response characteristic of more conventional ATIN.<sup>50</sup>

To some extent, this may explain why the aforementioned patient on combination ipilimumab and nivolumab therapy relapsed, necessitating high-dose immune suppression and MMF to control disease. CTLA-4 regulates peripheral tolerance by modulating the interaction between APCs and T cells in secondary lymphoid organs; PD-1 contributes to tolerance primarily at the level of the target organs. Blocking both pathways could synergistically potentiate antigen recognition and T-cell proliferation at the lymph nodes, as well as provoke unwanted cytotoxic T-cell effects in the periphery.<sup>51</sup>

The other mechanism suggested is that CPIs reduce tolerance to concomitant medications known to cause ATIN. It is noteworthy that in the Cortazar et al. and Shirali et al. case series, 14 of the combined 19 patients were on culprit drugs associated with ATIN, mostly PPIs and NSAIDs. This

suggests that CPIs may disrupt the CTLA-4 and PD-1 signaling that is critical to maintaining tolerance to medications like NSAIDs and/or PPIs — resulting in clinically significant ATIN. In this scenario, CTLA-4 and PD-1 inhibitor therapy reactivate exhausted drug-specific effector T cells previously primed by exposure to nephritogenic drugs.<sup>50</sup> This would have significant implications for this population, as *rechallenge* with CTLA-4 or PD-1 inhibitor therapy would seem reasonable if other potentially offending agents are withdrawn and ATIN has resolved.

## Clinical Features

Like ATIN from other etiologies, eosinophilia, rash, and fever are absent in the majority of cases of CPI-induced ATIN.<sup>52</sup> Eosinophilia was present in 21% of the patients from the larger case series. Some patients also presented with new or worsened hypertension (11%) and hematuria (16%).<sup>22,41</sup> When measured, complement levels were normal. Most had subnephrotic range proteinuria (median 0.48 g/g; range 0.12-0.98 g/g).<sup>22</sup> So far, nephrotic syndrome is a rare finding only associated with ipilimumab.<sup>27,28</sup>

Most patients will present with rising serum creatinine and pyuria; these appeared to be the only clinical clues in a large majority of the cases. In the Cortazar et al. study, median peak creatinine during AKI was 4.5 (3.6-7.3) mg/dL.<sup>22</sup> Two of the patients in the Shirali et al. case series were found to have WBC casts.<sup>41</sup>

Renal manifestations of more typical ATIN generally occur within 3 weeks of starting the offending drug in 80% of the cases, where the average delay is about 10 days with antibiotics.<sup>53</sup> A unique feature of CPI-induced ATIN is the much more heterogeneous time course from drug exposure to the development of AKI. As noted above in the Cortazar et al. series, the interval from initiation of CPI to AKI ranged from 3 to 35 weeks (median 13 weeks), while in Shirali et al., the interval was between 40 to 64 weeks.<sup>22,41</sup> The heterogeneity

of time course suggests that the time from drug exposure to disruption in tolerance — to endogenous kidney antigens and/or to possible co-offending medications — is variable across patients.

Another unique feature is the development of extrarenal immune-related adverse events. In the Cortazar et al. series, at least one extrarenal adverse event was documented prior to AKI onset in seven patients and concurrently with AKI in one additional patient. These adverse events were mostly hypophysitis and colitis.<sup>22</sup> Thus, the development of current or prior immune-related adverse events should raise suspicion of CPI-induced ATIN in a patient presenting with AKI. However, this may prove difficult since CPI-induced immune-related adverse events can affect virtually any organ system. Therefore, the difficult situation may arise wherein physicians may need to consider all symptoms as potentially CPI-associated.

### Pathology

Most authors have concluded that only renal biopsy is definitively diagnostic in CPI-induced ATIN.<sup>54</sup> Histological examination will reveal tubulitis and interstitial inflammation, consisting primarily of activated lymphocytes with varying degrees of macrophages and eosinophils.<sup>22,55</sup> Noncaseating granulomas were noted in three of the patients from the Cortazar et al. study.<sup>22</sup> Granulomatous interstitial nephritis that is nonnecrotizing has often been associated with sarcoidosis and drugs such as sulfonamides, penicillins, fluoroquinolones, NSAIDs, hydrochlorothiazide, and allopurinol. CPIs can most likely be added to this list of offenders.<sup>56</sup> Of note, it has been shown that drug-induced granulomatous interstitial nephritis has more diffuse interstitial involvement with a higher concentration of eosinophils and neutrophils.<sup>57</sup> Immunofluorescence examination will generally reveal no deposits.<sup>55</sup> Electron microscopy will be notable for the absence of electron-dense deposits.<sup>22</sup>

### Management

The mainstay of management of immune-related adverse events is immunosuppression, including high-dose steroids, MMF, and potentially, TNF- $\alpha$  inhibitors. The management of CPI-induced ATIN follows this general management strategy.<sup>19</sup> For a creatinine increase that is 1.5 to 2.0 times above baseline, close observation has been suggested. For higher-grade toxicity, CPI therapy should be withheld and steroids initiated.<sup>23</sup> Authors of the Shirali et al. study tentatively suggest prednisone 1 mg/kg with a 1-month taper. The use of other immune-modulatory agents, like MMF, have been used, but only rarely.<sup>33,39,41</sup> Furthermore, concomitant medications commonly associated with ATIN should be discontinued.<sup>58</sup> Given the limited sample size and observational nature of the studies, it must be stressed that the optimal steroid dose and treatment duration is currently unknown. This is hardly unique to CPIs though, as the use of steroids in the treatment of ATIN is largely controversial.<sup>59</sup>

There should also be close monitoring of serum creatinine while on CPI therapy. For patients on ipilimumab, pembrolizumab, and ipilimumab/nivolumab combination therapy, creatinine monitoring should be more frequent in the first 3 months, as the injury appears to happen earlier in the treatment course. Weekly creatinine monitoring for at least 1 month after completing steroid taper has also been suggested given the incidence of AKI relapse.<sup>41</sup>

Particularly worth investigating in this population is whether patients who develop CPI-induced ATIN can safely restart CPI therapy after ATIN has resolved. Early data suggests that nivolumab may be safely tolerated among patients who suffer high-grade immune-related adverse events while on ipilimumab, though the number of ATIN cases in this study was small.<sup>60</sup> In the case series by Cortazar et al., two patients were retreated with different CPI agents after partial renal recovery with steroids, while one restarted the same agent — all maintained relatively stable renal function on rechallenge

without AKI recurrence.<sup>22</sup> On the other hand, one patient from the Shirali et al. series redeveloped AKI after being restarted on ipilimumab/nivolumab therapy, but this outcome was confounded by ongoing PPI use.<sup>41</sup>

Most experts would recommend permanent discontinuation of the CPI if it leads to grade 3 or 4 toxicity.<sup>61</sup> As noted above, this would mean an increase in creatinine > 3-fold above baseline, an increase in creatinine to a level > 4.0 mg/dL, or the need for renal replacement therapy. Otherwise, based on the limited data presented above, rechallenging with CPI therapy may be reasonable if ATIN has been treated and other culprit medications are discontinued.

### Hyponatremia

Ipilimumab in particular is a well-recognized cause of several endocrine immune-related adverse events, such as hypophysitis, hypopituitarism, and very rarely, diabetes insipidus. Pituitary dysfunction occurred in 4.5% of patients in the largest ipilimumab trial.<sup>7</sup> Of note, case reports have

emerged describing ipilimumab-induced hyponatremia due to hypocortisolemia.<sup>62,63</sup> Mechanistically, a loss of ACTH-secreting corticotrophs leads to a loss of corticotropin-releasing hormone, which has regulatory effects on arginine vasopressin. In the hyponatremic patient presenting with bifrontal headaches described by Barnard et al., urine sodium was > 100 mEq/24h, urine osmolality was > 400 mOsm/kg, and ACTH and cortisol were both relatively low. MRI of the brain showed enlargement of the anterior pituitary gland with an area of necrosis consistent with hypophysitis. Of note, after withdrawal of ipilimumab therapy, these radiographic findings resolved and the patient was treated successfully with hydrocortisone.<sup>62</sup>

In contrast to ipilimumab, agents acting on PD-1 (nivolumab and pembrolizumab) are more commonly associated with thyroid dysfunction.<sup>64</sup> Although hypophysitis induced by nivolumab has also been reported, its incidence (< 1%) appears to be lower than that observed with ipilimumab.<sup>64,65</sup>

**Table 1: CTLA-4 antagonists and PD-1 inhibitors compared**

	<b>CTLA-4 antagonists</b>	<b>PD-1 inhibitors</b>
<b>FDA approval for</b>	Metastatic melanoma	Metastatic melanoma, NSCLC
<b>Risk of all-grade renal toxicity</b>	Higher risk compared to nivolumab monotherapy.	Pembrolizumab: higher risk than either ipilimumab or nivolumab monotherapies.
<b>Time course of ATIN onset</b>	Mostly 6 to 12 weeks after CPI initiation, but as early as 3 weeks and as late as 35 weeks.	Nivolumab: 40 to 64 weeks after CPI initiation. Pembrolizumab: 4 to 54 weeks.
<b>ATIN pathology</b>	Tubulitis and interstitial inflammation. Lupus glomerulonephritis and minimal change disease reported but rare.	Tubulitis and interstitial inflammation. No glomerulonephritis reported.
<b>Associated electrolyte disorders</b>	Hyponatremia due to hypophysitis/secondary adrenal insufficiency.	Hyponatremia less common, but rare cases reported due to hypophysitis/secondary adrenal insufficiency and primary adrenal insufficiency with adrenalitis.



Another case has been reported of nivolumab-induced adrenalitis resulting in primary adrenal failure presenting with hyponatremia. The hyponatremia failed to resolve entirely with hydrocortisone alone, but serum sodium promptly normalized with the addition of fludrocortisone.<sup>66</sup> Interestingly, long-term follow-up of endocrine immune-related adverse events suggests that on occasion thyroid function may recover, but that dysfunction of the corticosteroid axis is likely to be permanent.<sup>67</sup> None of the cases reviewed, however, described open-ended steroid therapy.

The bigger point here may be that not all cases of hyponatremia in malignancy are due to the syndrome of inappropriate antidiuretic hormone (SIADH), as is often the assumption. Hypocortisolemia must always be excluded as a potential cause of hyponatremia with immune checkpoint inhibitor therapy, especially in the case of ipilimumab.

## Conclusions

Although clinical studies show relatively small incidence, it is also possible that cases of CPI-induced ATIN were undetected or erroneously attributed to another etiology given the novelty of this entity. One must consider, however, that even if emerging data later suggests a higher incidence, the risk of AKI is likely outweighed by the benefits of CPI therapy in a patient population that often has few therapeutic options.

CPI-induced ATIN shares some characteristics with typical ATIN but is unique in its proposed mechanism of action, variable time course, and association with extrarenal immune-related adverse events. Due to the heterogeneous time course, all patients on CPI therapy probably need prolonged and regular creatinine monitoring. It is likely that early recognition of this entity is important to avoid development of significant fibrosis in the kidney.

There should be a low threshold to perform kidney biopsy in these patients. Clinical features tend to be nonspecific, so biopsy should be considered in cases of AKI in the setting of CPI therapy to confirm ATIN, or more rarely, glomerulopathy. This especially holds true in the cancer population, as making the wrong diagnosis could lead to unnecessary discontinuation of life-saving therapy, while initiating steroids could nullify the tumor-killing benefits provided by CPIs in the first place. One report, however, found that the use of steroids in patients treated with ipilimumab did not negatively affect survival or time-to-treatment failure.<sup>68</sup> Furthermore, several large studies have reported increased efficacy in patients affected by immune-related adverse events, with therapeutic response in 26% of patients experiencing any immune-related adverse event compared to 2% in patients who did not.<sup>69</sup> This suggests that the potentially life-threatening side effects of CPIs, like ATIN and hyponatremia, are also markers of therapeutic success.

No definitive treatment algorithm exists. When it comes to management of CPI-induced ATIN, the mainstay of treatment is discontinuing the CPI and all possible offending medications, as well as possibly initiating immune suppression. The latter consists of high-dose steroids and possibly MMF. Of course, the potential benefits of CPI therapy need to be weighed heavily against the risk of AKI.

## References

- Palucka AK, Coussens LM. The Basis of Oncoimmunology. *Cell*. 2016; 164(6): 1233-1247.
- Krummel MF, Allison JP. CTLA-4 Engagement Inhibits IL-2 Accumulation and Cell Cycle Progression Upon Activation of Resting T Cells. *J Exp Med*. 1996; 183(6): 2533-2540.
- Freeman GJ, Long AJ, Iwai Y, et al. Engagement of the PD-1 Immuno-inhibitory Receptor by a Novel B7 Family Member Leads to Negative Regulation of Lymphocyte Activation. *J Exp Med*. 2000; 192(7): 1027-1034.
- Postow MA, Callahan MK, Wolchok JD. Immune Checkpoint Blockade in Cancer Therapy. *J Clin Oncol*. 2015; 33(17): 1974-1982.
- Sharma P, Allison JP. The Future of Immune Checkpoint Therapy. *Science*. 2015; 348(6230): 56-61.
- Rosenberg SA, Yang JC, Restifo NP. Cancer Immunotherapy: Moving Beyond Current Vaccines. *Nat Med*. 2004; 10(9): 909-915.
- Hodi FS, O'Day SJ, McDermott DF, et al. Improved Survival With Ipilimumab in Patients With Metastatic Melanoma. *N Engl J Med*. 2010; 363(8): 711-723.
- Robert C, Thomas L, Bondarenko I, et al. Ipilimumab Plus Dacarbazine for Previously Untreated Metastatic Melanoma. *N Engl J Med*. 2011; 364(26): 2517-2526.
- Robert C, Long GV, Brady B, et al. Nivolumab in Previously Untreated Melanoma Without BRAF Mutation. *N Engl J Med*. 2015; 372(4): 320-330.
- Motzer RJ, Escudier B, McDermott DF, et al. Nivolumab Versus Everolimus in Advanced Renal-Cell Carcinoma. *N Engl J Med*. 2015; 373(19): 1803-1813.
- Brahmer J, Reckamp KL, Baas P, et al. Nivolumab Versus Docetaxel in Advanced Squamous-Cell Non-Small-Cell Lung Cancer. *N Engl J Med*. 2015; 373(2): 123-135.
- Garon EB, Rizvi NA, Hui R, et al. Pembrolizumab for the Treatment of Non-Small-Cell Lung Cancer. *N Engl J Med*. 2015; 372(21): 2018-2028.
- Robert C, Schachter J, Long GV, et al. Pembrolizumab Versus Ipilimumab in Advanced Melanoma. *N Engl J Med*. 2015; 372(26): 2521-2532.
- Chow LQ, Haddad R, Gupta S, et al. Antitumor Activity of Pembrolizumab in Biomarker-Unselected Patients With Recurrent and/or Metastatic Head and Neck Squamous Cell Carcinoma: Results From the Phase Ib KEYNOTE-012 Expansion Cohort. *J Clin Oncol*. 2016.
- Rosenberg JE, Hoffman-Censits J, Powles T, et al. Atezolizumab in Patients With Locally Advanced and Metastatic Urothelial Carcinoma Who Have Progressed Following Treatment With Platinum-based Chemotherapy: A Single-arm, Multicentre, Phase 2 Trial. *Lancet*. 2016; 387(10031): 1909-1920.
- Balar AV, Galsky MD, Rosenberg JE, et al. Atezolizumab as First-line Treatment in Cisplatin-ineligible Patients With Locally Advanced and Metastatic Urothelial Carcinoma: A Single-arm, Multicentre, Phase 2 Trial. *Lancet*. 2017; 389(10064): 67-76.
- Topalian SL, Hodi FS, Brahmer JR, et al. Safety, Activity, and Immune Correlates of Anti-PD-1 Antibody in Cancer. *N Engl J Med*. 2012; 366(26): 2443-2454.
- Brahmer JR, Tykodi SS, Chow LQ, et al. Safety and Activity of Anti-PD-L1 Antibody in Patients With Advanced Cancer. *N Engl J Med*. 2012; 366(26): 2455-2465.
- Weber JS, Kähler KC, Hauschild A. Management of Immune-related Adverse Events and Kinetics of Response With Ipilimumab. *J Clin Oncol*. 2012; 30(21): 2691-2697.
- Kourie HR, Klastersky J. Immune Checkpoint Inhibitors Side Effects and Management. *Immunotherapy*. 2016; 8(7): 799-807.
- Wanchoo R, Karam S, Uppal NN, et al. Adverse Renal Effects of Immune Checkpoint Inhibitors: A Narrative Review. *Am J Nephrol*. 2017; 45(2): 160-169.
- Cortazar FB, Marrone KA, Troxell ML, et al. Clinicopathological Features of Acute Kidney Injury Associated With Immune Checkpoint Inhibitors. *Kidney Int*. 2016; 90(3): 638-647.
- Abdel-Rahman O, Fouad M. A Network Meta-analysis of the Risk of Immune-related Renal Toxicity in Cancer Patients Treated With Immune Checkpoint Inhibitors. *Immunotherapy*. 2016; 8(5): 665-674.
- Vogel WV, Guislain A, Kvistborg P, Schumacher TN, Haanen JB, Blank CU. Ipilimumab-induced Sarcoidosis in a Patient With Metastatic Melanoma Undergoing Complete Remission. *J Clin Oncol*. 2012; 30(2): e7-e10.
- Wilgenhof S, Neyns B. Anti-CTLA-4 Antibody-induced Guillain-Barré Syndrome in a Melanoma Patient. *Ann Oncol*. 2011; 22(4): 991-993.
- Voskens CJ, Goldinger SM, Loquai C, et al. The Price of Tumor Control: An Analysis of Rare Side Effects of Anti-CTLA-4 Therapy in Metastatic Melanoma From the Ipilimumab Network. *PLoS One*. 2013; 8(1): e53745.
- Fadel F, El Karoui K, Knebelmann B. Anti-CTLA4 Antibody-induced Lupus Nephritis. *N Engl J Med*. 2009; 361(2): 211-212.
- Kidd JM, Gizaw AB. Ipilimumab-associated Minimal-change Disease. *Kidney Int*. 2016; 89(3): 720.
- O'Day SJ, Maio M, Chiarion-Sileni V, et al. Efficacy and Safety of Ipilimumab Monotherapy in Patients With Pretreated Advanced Melanoma: A Multicenter Single-arm Phase II Study. *Ann Oncol*. 2010; 21(8): 1712-1717.
- Forde PM, Rock K, Wilson G, O'Byrne KJ. Ipilimumab-induced Immune-related Renal Failure--A Case Report. *Anticancer Res*. 2012; 32(10): 4607-4608.
- Izzedine H, Gueutin V, Gharbi C, et al. Kidney Injuries Related to Ipilimumab. *Invest New Drugs*. 2014; 32(4): 769-773.
- Beck KE, Blansfield JA, Tran KQ, et al. Enterocolitis in Patients With Cancer After Antibody Blockade of Cytotoxic T-lymphocyte-associated Antigen 4. *J Clin Oncol*. 2006; 24(15): 2283-2289.
- Thajudeen B, Madhrira M, Bracamonte E, Cranmer LD. Ipilimumab Granulomatous Interstitial Nephritis. *Am J Ther*. 2015; 22(3): e84-87.
- Topalian SL, Sznol M, McDermott DF, et al. Survival, Durable Tumor Remission, and Long-term Safety in Patients With Advanced Melanoma Receiving Nivolumab. *J Clin Oncol*. 2014; 32(10): 1020-1030.
- Weber JS, D'Angelo SP, Minor D, et al. Nivolumab Versus Chemotherapy in Patients With Advanced Melanoma Who Progressed After Anti-CTLA-4 Treatment (CheckMate 037): A Randomised, Controlled, Open-label, Phase 3 Trial. *Lancet Oncol*. 2015; 16(4): 375-384.
- Postow MA, Chesney J, Pavlick AC, et al. Nivolumab and Ipilimumab Versus Ipilimumab in Untreated Melanoma. *N Engl J Med*. 2015; 372(21): 2006-2017.
- Wolchok JD, Kluger H, Callahan MK, et al. Nivolumab Plus Ipilimumab in Advanced Melanoma. *N Engl J Med*. 2013; 369(2): 122-133.

38. Larkin J, Hodi FS, Wolchok JD. Combined Nivolumab and Ipilimumab or Monotherapy in Untreated Melanoma. *N Engl J Med*. 2015; 373(13): 1270-1271.
39. Murakami N, Borges TJ, Yamashita M, Riella LV. Severe Acute Interstitial Nephritis After Combination Immune-checkpoint Inhibitor Therapy for Metastatic Melanoma. *Clin Kidney J*. 2016; 9(3): 411-417.
40. Vandiver JW, Singer Z, Harshberger C. Severe Hyponatremia and Immune Nephritis Following an Initial Infusion of Nivolumab. *Target Oncol*. 2016; 11(4): 553-556.
41. Shirali AC, Perazella MA, Gettinger S. Association of Acute Interstitial Nephritis With Programmed Cell Death 1 Inhibitor Therapy in Lung Cancer Patients. *Am J Kidney Dis*. 2016; 68(2): 287-291.
42. Min L, Hodi FS. Anti-PD1 Following Ipilimumab for Mucosal Melanoma: Durable Tumor Response Associated With Severe Hypothyroidism and Rhabdomyolysis. *Cancer Immunol Res*. 2014; 2(1): 15-18.
43. Waterhouse P, Penninger JM, Timms E, et al. Lymphoproliferative Disorders With Early Lethality in Mice Deficient in CTLA-4. *Science*. 1995; 270(5238): 985-988.
44. Tivol EA, Borriello F, Schweitzer AN, Lynch WP, Bluestone JA, Sharpe AH. Loss of CTLA-4 Leads to Massive Lymphoproliferation and Fatal Multiorgan Tissue Destruction, Revealing a Critical Negative Regulatory Role of CTLA-4. *Immunity*. 1995; 3(5): 541-547.
45. Kuehn HS, Ouyang W, Lo B, et al. Immune Dysregulation in Human Subjects With Heterozygous Germline Mutations in CTLA-4. *Science*. 2014; 345(6204): 1623-1627.
46. Schubert D, Bode C, Kenefeck R, et al. Autosomal Dominant Immune Dysregulation Syndrome in Humans With CTLA-4 Mutations. *Nat Med*. 2014; 20(12): 1410-1416.
47. Waeckerle-Men Y, Starke A, Wüthrich RP. PD-L1 Partially Protects Renal Tubular Epithelial Cells From the Attack of CD8+ Cytotoxic T cells. *Nephrol Dial Transplant*. 2007; 22(6): 1527-1536.
48. Nishimura H, Nose M, Hiai H, Minato N, Honjo T. Development of Lupus-like Autoimmune Diseases by Disruption of the PD-1 Gene Encoding an ITIM Motif-carrying Immunoreceptor. *Immunity*. 1999; 11(2): 141-151.
49. Zheng G, Wang Y, Mahajan D, Qin X, Alexander SI, Harris DC. The Role of Tubulointerstitial Inflammation. *Kidney Int Suppl*. 2005; (94): S96-100.
50. Spanou Z, Keller M, Britschgi M, et al. Involvement of Drug-specific T cells in Acute Drug-induced Interstitial Nephritis. *J Am Soc Nephrol*. 2006; 17(10): 2919-2927.
51. Das R, Verma R, Sznol M, et al. Combination Therapy With Anti-CTLA-4 and Anti-PD-1 Leads to Distinct Immunologic Changes In Vivo. *J Immunol*. 2015; 194(3): 950-959.
52. Muriithi AK, Leung N, Valeri AM, et al. Biopsy-proven Acute Interstitial Nephritis, 1993-2011: A Case Series. *Am J Kidney Dis*. 2014; 64(4): 558-566.
53. Rossert J. Drug-induced Acute Interstitial Nephritis. *Kidney Int*. 2001; 60(2): 804-817.
54. Perazella MA. Checkmate: Kidney Injury Associated With Targeted Cancer Immunotherapy. *Kidney Int*. 2016; 90(3): 474-476.
55. Tanaka A, Ikinaga K, Kiyohara E, et al. Critical Renal Adverse Event Induced by Nivolumab Therapy in a Stage IV Melanoma Patient. *J Dermatol*. 2016.
56. Shah S, Carter-Monroe N, Atta MG. Granulomatous Interstitial Nephritis. *Clin Kidney J*. 2015; 8(5): 516-523.
57. Bijol V, Mendez GP, Nosé V, Rennke HG. Granulomatous Interstitial Nephritis: A Clinicopathologic Study of 46 Cases From a Single Institution. *Int J Surg Pathol*. 2006; 14(1): 57-63.
58. Geevasinga N, Coleman PL, Webster AC, Roger SD. Proton Pump Inhibitors and Acute Interstitial Nephritis. *Clin Gastroenterol Hepatol*. 2006; 4(5): 597-604.
59. Clarkson MR, Giblin L, O'Connell FP, et al. Acute Interstitial Nephritis: Clinical Features and Response to Corticosteroid Therapy. *Nephrol Dial Transplant*. 2004; 19(11): 2778-2783.
60. Weber J, Gibney G, Kudchadkar R, et al. Phase I/II Study of Metastatic Melanoma Patients Treated With Nivolumab Who Had Progressed After Ipilimumab. *Cancer Immunol Res*. 2016; 4(4): 345-353.
61. Spain L, Diem S, Larkin J. Management of Toxicities of Immune Checkpoint Inhibitors. *Cancer Treat Rev*. 2016; 44: 51-60.
62. Barnard ZR, Walcott BP, Kahle KT, Nahed BV, Coumans JV. Hyponatremia Associated With Ipilimumab-induced Hypophysitis. *Med Oncol*. 2012; 29(1): 374-377.
63. Chodakiewicz Y, Brown S, Boxerman JL, Brody JM, Rogg JM. Ipilimumab Treatment Associated Pituitary Hypophysitis: Clinical Presentation and Imaging Diagnosis. *Clin Neurol Neurosurg*. 2014; 125: 125-130.
64. Torino F, Corsello SM, Salvatori R. Endocrinological Side-effects of Immune Checkpoint Inhibitors. *Curr Opin Oncol*. 2016; 28(4): 278-287.
65. Okano Y, Satoh T, Horiguchi K, et al. Nivolumab-induced Hypophysitis in a Patient With Advanced Malignant Melanoma. *Endocr J*. 2016; 63(10): 905-912.
66. Trainer H, Hulse P, Higham CE, Trainer P, Lorigan P. Hyponatraemia Secondary to Nivolumab-induced Primary Adrenal Failure. *Endocrinol Diabetes Metab Case Rep*. 2016; 2016.
67. Weber JS, Yang JC, Atkins MB, Disis ML. Toxicities of Immunotherapy for the Practitioner. *J Clin Oncol*. 2015; 33(18): 2092-2099.
68. Horvat TZ, Adel NG, Dang TO, et al. Immune-Related Adverse Events, Need for Systemic Immunosuppression, and Effects on Survival and Time to Treatment Failure in Patients With Melanoma Treated With Ipilimumab at Memorial Sloan Kettering Cancer Center. *J Clin Oncol*. 2015; 33(28): 3193-3198.
69. Downey SG, Klapper JA, Smith FO, et al. Prognostic Factors Related to Clinical Response in Patients With Metastatic Melanoma Treated by CTL-associated Antigen-4 Blockade. *Clin Cancer Res*. 2007; 13(22 Pt 1): 6681-6688.

200 Lothrop St.  
Pittsburgh, PA 15213-2582

[UPMCPhysicianResources.com/Kidney](http://UPMCPhysicianResources.com/Kidney)



**ADDRESS CORRESPONDENCE TO:**

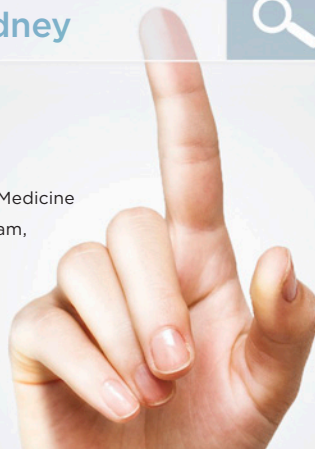**Helbert Rondon-Berrios, MD, FACP, FASN**

Assistant Professor of Medicine, University of Pittsburgh School of Medicine

Associate Program Director, Nephrology Fellowship Training Program,  
UPMC Renal-Electrolyte Division

A915 Scaife Hall  
3550 Terrace St.  
Pittsburgh, PA 15261

Phone: 412-647-3120  
Fax: 412-647-6220  
Email: [rondonberriosh@upmc.edu](mailto:rondonberriosh@upmc.edu)



A \$14 billion world-renowned health care provider and insurer, Pittsburgh-based UPMC is inventing new models of patient-centered, cost-effective, accountable care. UPMC provides nearly \$900 million a year in benefits to its communities, including more care to the region's most vulnerable citizens than any other health care institution. The largest nongovernmental employer in Pennsylvania, UPMC integrates 65,000 employees, more than 25 hospitals, 600 doctors' offices and outpatient sites, and a 3.2 million-member Insurance Services Division, the largest medical and behavioral health services insurer in western Pennsylvania. Affiliated with the University of Pittsburgh Schools of the Health Sciences, UPMC is on the prestigious *U.S. News & World Report* annual Honor Roll of America's Best Hospitals. UPMC Enterprises functions as the innovation and commercialization arm of UPMC, while UPMC International provides hands-on health care and management services with partners in 12 countries on four continents. For more information, go to [UPMC.com](http://UPMC.com).

## ABOUT THE RENAL-ELECTROLYTE DIVISION

The Renal-Electrolyte Division is devoted to clinical care and academic excellence, and training the next generation of nephrologists. Our multidisciplinary approach provides the highest quality care for patients with complex kidney and electrolyte disorders.

- Inpatient services at UPMC Presbyterian tend to patients awaiting or who have received kidney transplants, and the on-site dialysis center performs nearly 10,000 dialysis treatments a year in various ICU settings.
- Outpatient services are provided at our specialized kidney and multidisciplinary clinics treating a variety of kidney and hypertensive disorders.
- The Pittsburgh Center for Kidney Research, one of seven nationwide NIDDK-supported George M. O'Brien Kidney Research Core Centers, supports more than 140 investigators and provides funding for pilot projects.